

Epignathus with Fetiform Features

Kumar Sunil Y, Shrikrishna U¹, Jayaprakash Shetty, Aishwarya Sitaram

Departments of Pathology and ¹Radiology, KS Hegde Medical Academy, Deralakatte, Mangalore, India

Address for correspondence: Dr. Sunil Kumar Y, E-mail: drsunilkumary@rediffmail.com

ABSTRACT

Epignathus is an extremely rare oropharyngeal teratoma that commonly arises from the palate, leading to a high mortality (80–100%) due to airway obstruction in the neonatal period. We present a case of epignathus immature teratoma with fetiform features, originating from basisphenoid in a 28-week preterm male baby, who succumbed to death immediately after birth. Since epignathus is a life-threatening condition at the time of delivery, a prenatal diagnosis is essential to coordinate the treatment and appropriate management by securing the airway, either by endotracheal intubation or tracheostomy followed by complete resection of the tumor.

Keywords: Epignathus, fetiform, immature teratoma, resection

INTRODUCTION

Epignathus is a rare oropharyngeal teratoma arising from upper jaw, palate and sphenoid bone.^[1-4] Its incidence ranges from 1:35,000 to 200,000 live births and has a female predominance.^[1,5,6] An immature component with associated signs of malignancy is rare.^[1,2,7] We present a case of a 25-year-old female who presented to the emergency department with 7 months of amenorrhea and abdominal pain and delivered a male baby with huge mandibular mass which was later confirmed as epignathus with fetiform features. Since the baby had respiratory distress, the pediatrician tried to revive the baby; unfortunately, the baby succumbed to death. We hereby emphasize the prenatal diagnosis of these tumors by radiological examination so that an aggressive multidisciplinary treatment approach can be planned after delivery.^[7] Although prenatal diagnosis of these life-threatening tumors is essential, managing them in well-equipped hospitals with multidisciplinary facilities for resuscitation and later resection of the tumor is required to reduce the mortality.

CASE REPORT

A 25-year-old female presented to the emergency department with 7 months of amenorrhea and abdominal pain. She had regular antenatal checkups in a rural hospital, with uneventful first trimester. Antenatal abdominopelvic ultrasound done in that rural hospital at 24 weeks showed a single, live intrauterine fetus with mild polyhydramnios. Examination in our hospital revealed full-term uterus, with inability to palpate the fetal parts. Fetal heart sounds were heard, but feeble. Ultrasound examination revealed severe polyhydramnios and a single live fetus of gestational age 28–29 weeks with cephalic presentation associated with a huge mixed echogenic mass lesion measuring 10 × 8 × 6 cm on the anterior surface of the mandible. A diagnosis of mandibular mass with severe polyhydramnios was made. In view of fetal distress, an emergency lower segment cesarean section was undertaken, and she delivered a male baby weighing 1.35 kg. The baby had a huge pedunculated mass protruding from the oral cavity, arising from the posterior end of palate. Since the baby was in severe respiratory distress, the pediatrician tried to revive and secure the airway, but unfortunately the baby succumbed to death.

On autopsy, a pedunculated mass arising from the posterior end of palate through the basisphenoid, measuring 9.5 × 7.5 × 6 cm, was seen protruding from the oral cavity [Figure 1a]. The external surface showed

Access this article online	
Quick Response Code: 	Website: www.jlponline.org
	DOI: 10.4103/0974-2727.78571

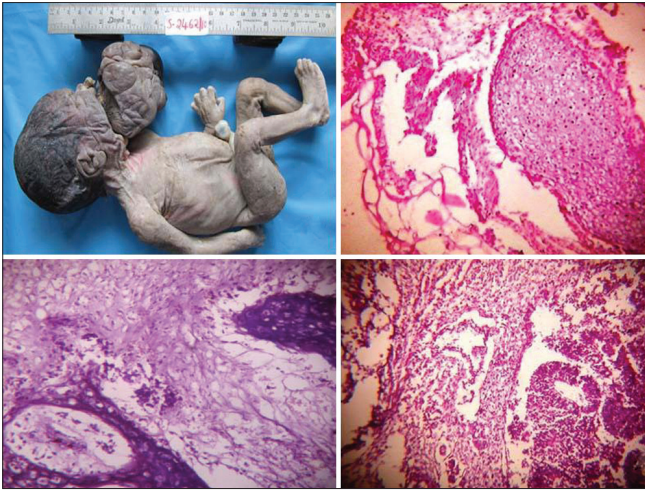

Figure 1: (a) Gross photograph of the dead male baby showing huge intraoral mass. (b) Microphotograph of the mass showing cartilage, adipocytes and smooth muscle tissue (H and E stain, 10x). (c) Microphotograph showing bony tissue and adipocytes (H and E stain, 10x). (d) Microphotograph showing immature neuroectodermal epithelium (H and E stain, 10x)

bilaterally symmetrical skin buds appearing like developing fetal parts. A postmortem plain radiograph [Figure 2a, b] and computed tomography (CT) scan [Figure 2c, d] revealed a heterogeneous dense mass arising from basisphenoid, with no intracranial extension. Cut section of the mass showed variegated appearance, fat tissue and bony areas. Microscopically, the mass was composed of mature components of all the three germ cell layers comprising stratified squamous epithelium, nervous tissue, intestinal epithelium, respiratory epithelium, cartilage, bony tissue, skeletal muscle, adipose tissue and blood vessels [Figure 1b, c]. Foci of immature neuroepithelial components comprising small round cells forming rosettes and tubules were also found [Figure 1d]. So, a final diagnosis of epignathus immature teratoma (grade 1) with fetiform features was made.

DISCUSSION

Ehlich classified oropharyngeal tumors according to the site of origin as episphenoid, epipalatine and epignathus tumors.^[2] The incidence of epignathus is between 1 in 35,000 and 200,000 live births.^[5] Nogales *et al.* reported a single case of epignathus in 800,000 deliveries in east Andalusia.^[2] They occur predominately in female babies at a ratio of 3:1 and originate from craniopharyngeal canal or Rathke's pouch.^[2,3] The present case was a male baby and the site of origin was basisphenoid. Teratomas in newborn can also occur in saccococcygeal region (commonest site), gonads, head and neck, mediastinum, retroperitoneum, brain, spinal cord and liver. Malformations associated with epignathus are cleft palate (commonest), bifid tongues

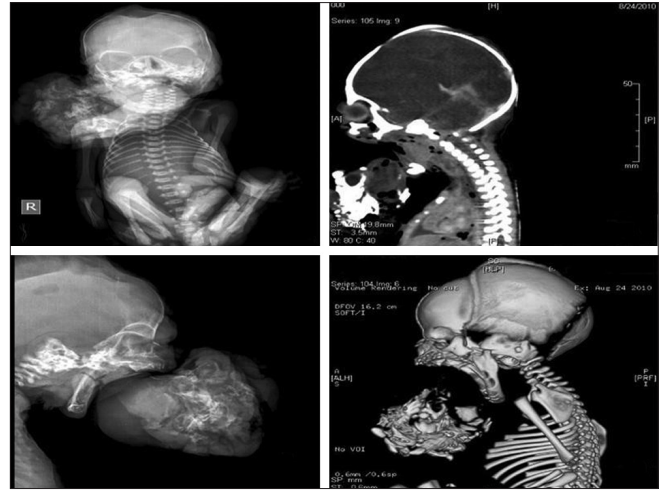


Figure 2: (a) Postmortem plain anteroposterior radiograph of the baby showing heterogeneously dense intraoral mass. (b) Lateral view of the mass. (c) Sagittal reformatted CT scan showing heterogeneous density mass arising from basisphenoid with no intracranial extension. (d) Sagittal view with 3D reconstruction

and bifid nose.^[2] Epignathus can be associated with Pierre Robin syndrome, with features like cleft palate, glossoptosis, and microretrognathia.^[2,8] However, our case had no other malformations. Many theories have been postulated for the etiopathogenesis of these tumors such as incomplete attempt to formation of Siamese twins from the 3rd week of gestation, persistence of a totipotent cell during embryogenesis and parthenogenetic transformation of a germ cell to a teratoma.^[2] Cytogenetic studies of epignathus and other extragonadal teratomas usually show a karyotype identical to that of the host, suggesting a mitotic origin from a totipotential diploid cell.^[2] Malignant change in epignathus is very rare.^[1,2,7] Associated preeclampsia and increase in amniotic alpha-fetoprotein (AFP) have been described.^[2] In our case, the mother had no preeclampsia and amniotic fluid AFP levels were not measured since the diagnosis of epignathus was not suspected. A prenatal diagnosis either by abdominopelvic ultrasound or magnetic resonance imaging (MRI) is the most important step in the management of these life-threatening lesions.^[2,3,9,10] This will determine its relationship to surrounding structures, its extension and any complications caused by the tumor. Mortality rates associated with large teratomas in the head and neck are generally high in the absence of a well-prepared resuscitation team or meticulous delivery planning to secure the airway. The patient's airway must be secured either by endotracheal intubation or tracheostomy. A purely endoscopic transpalatal endonasal approach is an excellent alternative for the conventional transfacial approach.^[5] Recent advances in multidisciplinary management of epignathus include *EX utero* Intrapartum Technique (EXIT procedure)^[4] or the Operation On Placental Support

(OOPS procedure).^[4,8] This technique leaves an intact fetoplacental circulation which confirms normal fetal oxygenation, while fetal airway patency is secured either by tracheal intubation or tracheostomy. Once a stable airway is obtained, the cord is clamped and infant stabilized. In our case, since the baby was in severe respiratory distress, the pediatrician tried to secure the airway, but unfortunately, the baby succumbed to death.

We hereby conclude that although prenatal diagnosis of these life-threatening tumors is essential, managing them in well-equipped hospitals with multidisciplinary facilities for resuscitation and later resection of the tumor is required to reduce the mortality.^[3,11-15]

REFERENCES

1. SC Too, Ahmad Sarji S, Syi Yik, TM Ramanujam. Malignant epignathus teratoma. *Biomed Imaging Interv J* 2008;4:18.
2. Vandenhoute B, Leteurtre, Leconte-Houche M, Pallerin P, Nayts JP, Luisset JM, *et al.* Epignathus teratoma: Report of three cases with a review of the literature. *Cleft Palate-Craniofacial J* 2000;37:83-91.
3. Kumar B, Shyam BS. Neonatal oral tumors: Congenital epulis and epignathus. *J Pediatr Surg* 2008;43:9-11.
4. Lionel J, Valvodo M, Hadi K, Abdul A. Giant epignathus-A case report. *Kuwait Med J* 2004;36:217-20.
5. Prevedello MD, Kassam BA, Carrau LR, Snyderman HC, Thomas A, Garner P. Transpalatal endoscopic endonasal resection of a giant epignathus skull base teratoma in a new born. *J Neurosurg* 2007;107:266-71.
6. Frietas RD, Alonso N, Azzolini TD, Gianini-Romano G, Tolazzi AR, Busato I, *et al.* Epignathus: Two cases. *Br J Oral Maxillofac Surg* 2008;46:317-9.
7. Holmegren G, Rydnert J. Male fetus with epignathus originating from the ethmoidal sinus. *Eur J Obstet Gynecol Reprod Biol* 1987;24:69-72.
8. Sanchez AV, Moreno HC, Salfado AS, Serena JC, Irra EJ, Sanchez PG, *et al.* Epignathus. *Cleft Palate Craniofac J* 2000;37:83-91.
9. Peter WC. *Ultrasonography in obstetrics and gynaecology*. 4th ed, Philadelphia: Saunders-An imprint of Elsevier; 2000. p. 316-38.
10. Rumack MC, Wilson RS, Charboneau WJ. *Diagnostic ultrasound*. 3rd ed, Vol. 2. Netherlands: Mosby- An imprint of Elsevier; 2009. P. 1225-6.
11. Johnston JM, Vyas NA, Kane AA, Molter DW, Smyth MD. Giant intracranial teratoma with epignathus in a neonate: Case report and review of literature. *J Neurosurg* 2007;106:232-6.
12. Okafor CI, Okafor CO, Odike MA. Congenital teratoma of the face. *J Obstet Gynaecol* 2004;24:828-9.
13. Zakaria MA. Epignathus (congenital teratoma of the hard palate): A case report. *Br J Oral Maxillofac Surg* 1986;24:272-6.
14. Becker S, Schon R, Gutwald R, Otten JE, Maier W, Hentschel R, *et al.* A congenital teratoma with a cleft palate. Report of a case. *Br J Oral Maxillofac Surg* 2007;45:326-7.
15. Chattopadhyay A, Patra R, Kumar V. Oral tumors in newborn. *India J Pediatr* 2003;70:587-8.

How to cite this article: Kumar SY, Shrikrishna U, Shetty J, Sitaram A. Epignathus with fetiform features. *J Lab Physicians* 2011;3:56-8.

Source of Support: Nil. **Conflict of Interest:** None declared.

Announcement

“QUICK RESPONSE CODE” LINK FOR FULL TEXT ARTICLES

The journal issue has a unique new feature for reaching to the journal's website without typing a single letter. Each article on its first page has a “Quick Response Code”. Using any mobile or other hand-held device with camera and GPRS/other internet source, one can reach to the full text of that particular article on the journal's website. Start a QR-code reading software (see list of free applications from <http://tinyurl.com/yzlh2tc>) and point the camera to the QR-code printed in the journal. It will automatically take you to the HTML full text of that article. One can also use a desktop or laptop with web camera for similar functionality. See <http://tinyurl.com/2bw7fn3> or <http://tinyurl.com/3ysr3me> for the free applications.