



Bland Urine Sediment in a Child with Acute Kidney Injury

Rajkumar Kundavaram¹ Tanya Sharma² Deepti Joshi² Amber Kumar¹ Shikha Malik¹ Girish C. Bhatt¹

¹Department of Pediatrics, All India Institute of Medical Sciences Bhopal, Bhopal, Madhya Pradesh, India

²Department of Pathology and Lab Medicine, All India Institute of Medical Sciences Bhopal, Bhopal, Madhya Pradesh, India

Address for correspondence Tanya Sharma, MD, Department of Pathology and Lab Medicine, All India Institute of Medical Sciences Bhopal, Saket Nagar, Bhopal, Madhya Pradesh, 462024, India (e-mail: tanya.patho@aiimsbhopal.edu.in).

J Lab Physicians 2023;15:152–155.

Abstract

Tubulointerstitial nephritis (TIN) or acute interstitial nephritis (AIN) is a renal lesion characterized by inflammatory infiltrate limited to the renal interstitium and tubules. Three-fourths of the cases are drug induced, other causes being systemic and autoimmune diseases, and infections. Various drugs have been implicated, the most common being antibiotics such as β -lactams. Cephalosporins causing AIN have been reported uncommonly, particularly in children. Although renal biopsy confirms the diagnosis, urinalysis provides pertinent diagnostic clues against the backdrop of the clinico-laboratory profile. The presence of white blood cells, white cell casts, and red blood cells in urine sediment have been described in literature. However, a relatively normal urinalysis may be present in some cases and may pose a diagnostic challenge. We present a case of ceftriaxone-induced AIN in a child with bland urine sediment at initial presentation. To the best of our knowledge, this is the first report of ceftriaxone-induced AIN in the pediatric age group.

Keywords

- ▶ acute interstitial nephritis
- ▶ acute kidney injury
- ▶ drug induced
- ▶ urine sediment

Introduction

Tubulointerstitial nephritis (TIN) or acute interstitial nephritis (AIN) is a renal lesion characterized by inflammatory infiltrate limited to the renal interstitium and tubules. It accounts for the third-most common cause of acute kidney injury (AKI) among hospitalized children.^{1,2} Three-fourth of the cases are drug induced, other causes being systemic and autoimmune diseases, and infections.³ Various drugs have been implicated, most common being antibiotics such as β -lactams. Cephalosporins causing AIN have been reported uncommonly, particularly in children. Patients with AIN may present with non-specific symptoms such as malaise and nausea or may sometimes be asymptomatic. Triad of rash,

fever, and peripheral blood eosinophilia is present in approximately 10% of cases of drug-induced acute interstitial nephritis (DI-AIN).⁴ Elevated serum creatinine levels are virtually present in all cases of TIN. Further, eosinophiluria (defined as $\geq 1\%$ of urinary white cells) may be present in variable numbers of drug-induced TIN.^{5,6} Although renal biopsy confirms the diagnosis, urinalysis provides pertinent diagnostic clues in a backdrop of clinical and other laboratory parameters. The presence of white blood cells, white blood cell casts, and red blood cells in urine sediment have been described in the literature. However, a relatively normal urinalysis may be present in some cases, and may present a diagnostic challenge. We present a case of

article published online
August 17, 2022

DOI <https://doi.org/10.1055/s-0042-1750068>.
ISSN 0974-2727.

© 2022. The Indian Association of Laboratory Physicians. All rights reserved.

This is an open access article published by Thieme under the terms of the Creative Commons Attribution-NonDerivative-NonCommercial-License, permitting copying and reproduction so long as the original work is given appropriate credit. Contents may not be used for commercial purposes, or adapted, remixed, transformed or built upon. (<https://creativecommons.org/licenses/by-nc-nd/4.0/>)

Thieme Medical and Scientific Publishers Pvt. Ltd., A-12, 2nd Floor, Sector 2, Noida-201301 UP, India

ceftriaxone-induced AIN in a child with bland urine sediment at initial presentation.

Case Report

A 2-year-old male asymptomatic child was referred to the pediatric outpatient department in view of elevated blood urea and creatinine levels. On elaboration of history, parents revealed that child had an episode of fever with diarrhea and vomiting 1 week prior for 3 days, for which he had received intravenous ceftriaxone (for 3 days) and supportive treatment at a local hospital. His symptoms had improved; however, his blood urea and creatinine levels were persistently elevated, for which he was referred at our facility. Child had no history of edema, hematuria, or reduced urine output. On initial evaluation, the child was clinically stable and there were no signs of dehydration. Examination revealed non-purpuric rashes over the body. There was no evidence of redness of the eyes, ocular pain, or photophobia. Blood Pressure was between 50th to 90th percentile. Complete blood count revealed hemoglobin 8.3 g%, total leucocyte count $11,700/\text{mm}^3$, and platelet count $5.98 \text{ lacs}/\text{mm}^3$. Red blood cells were mainly microcytic hypochromic with the absence of schistocytes, thrombocytopenia, eosinophilia, or reticulocytosis. Urine examination sent on day 1 showed bland urine sediment with the absence of proteinuria, hematuria, and cellular elements or casts. Serum creatinine was 7.89 mg/dL and blood urea nitrogen was 282 mg/dL. Blood gas and serum electrolytes levels were within normal limits. Antinuclear antibody (ANA) and antinuclear cytoplasmic antibody (ANCA) serology was negative and serum complement levels as well as anti-streptolysin antibody titers were in normal range. Real-time reverse transcription polymerase chain reaction (rRT-PCR) for COVID-19 was negative. Urine culture and sensitivity showed no growth. Ultrasonography of the kidneys, ureters, and bladder (KUB) revealed normal-sized kidneys with bilateral grade 2 renal parenchymal changes. Fractional excretion of sodium was elevated (8.9%).

A diagnosis of acute kidney injury (AKI) of renal origin was made and the child was further investigated for the cause of AKI and was conservatively managed as his urine output was greater than 1.5 mL/kg/day with normal serum electrolytes and decreasing trend of urea and creatinine. There was progressive decline in serum creatinine and blood urea nitrogen levels over a period of 1 week, which dropped to 2.67 mg/dL and 132 mg/dL, respectively. However, the levels did not fall below baseline or normal range and repeat urinalysis revealed the presence of trace proteinuria, epithelial cells 3–4/high power field (hpf), white blood cells 10–11/hpf, and red blood cells 14–15/hpf. A renal biopsy was advised with a clinical diagnosis of acute interstitial nephritis.

Light microscopy of renal biopsy revealed largely unremarkable glomeruli with no evidence of significant endocapillary or extracapillary proliferation or sclerosis. Tubules showed features of tubular injury in the form of vacuolation and loss of tubular cells along with focal lymphocytic infiltrate into the tubular epithelium. A few of the tubules were

cystically dilated with the presence of hyaline casts. The interstitium showed moderate interstitial inflammatory infiltrate comprising predominately lymphocytes along with macrophages and edema. One focus of dense lymphocytic aggregate was seen. No definite eosinophilic infiltrate was seen. No significant interstitial fibrosis was seen. Blood vessels were unremarkable, without evidence of vasculitis (– Fig. 1). Direct immunofluorescence was negative for IgG, IgA, IgM, C3, and C1q. A diagnosis of tubulointerstitial nephritis, most probably due to ceftriaxone therapy was confirmed.

The child was started on oral prednisolone 1 mg/kg/day for 4 weeks following which, the renal function tests (RFTs) normalized with unremarkable urinalysis. The patient was followed up with tapering doses of steroids.

Discussion

Tubulointerstitial nephritis (TIN) or acute interstitial nephritis (AIN) is characterized by acute kidney injury associated with acute or chronic inflammatory infiltrate in the renal interstitium. Diagnosis of TIN should be suspected in a patient who presents with an elevated serum creatinine and an abnormal urinalysis showing white cells, white cell casts, and, in some cases, eosinophiluria. However, a normal urinalysis at initial presentation may pose diagnostic dilemma.

There are limited studies describing the findings of urinary sediment in TIN. The common findings include pyuria (sterile), WBC casts, and sometimes red blood cells. The presence of red blood cell casts, granular casts, and renal tubular epithelial cells have also been described in the literature.³ Fogazzi et al studied 21 cases of biopsy-proven AIN and found that urine sediment showed WBCs in 12

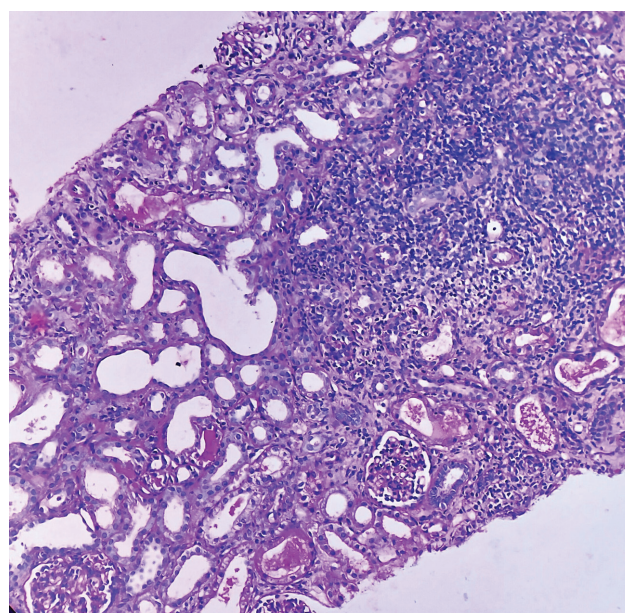


Fig. 1 Renal biopsy showing interstitial chronic inflammatory infiltrate and edema with features of tubular injury. The glomeruli are unremarkable (periodic acid schiff [PAS], $20\times$).

patients (57.1%), RBCs in 10 (47.6%), renal tubular epithelial cells (RTECs) in 3 (14.2%), and casts in 20 (95.2%), in various combinations. Additionally, RBC casts were found in 6 patients (28.5%).⁷ In the present case, initial urinalysis revealed no active urine sediments, with the absence of proteinuria, white or red blood cells, and casts. A few studies have reported bland urine sediment in cases of AIN, which may frequently be misinterpreted as the prerenal cause. However, diagnosis of AIN should not be excluded based on bland urine sediment.^{3,8,9} Further, fractional excretion of sodium (FeNa) may also be useful to distinguish the prerenal cause from the renal cause of AKI. In the present case, although the initial urinalysis revealed no abnormality, the patient developed proteinuria and hematuria with the presence of WBCs and RBCs over time.

The most common cause of acute interstitial nephritis include drug therapy and infections. Numerous drugs responsible for acute interstitial nephritis have been described in the literature, which include antibiotics, specifically β -lactams (penicillin and methicillin), nonsteroidal anti-inflammatory drugs, and diuretics.^{4,10,11} Cephalosporin-induced acute interstitial nephritis including cefepime- and ceftriaxone-induced acute interstitial nephritis has also been reported previously.¹²⁻¹⁴ A few studies have reported interstitial nephritis in children following the use of amoxicillin.^{15,16} In the present case, ceftriaxone was the likely cause of AIN. The World Health Organization (WHO) recommends oral rehydration and zinc for the management of diarrhea in children, and antimicrobials are not indicated in most diarrheal episodes in children.¹⁷ However, in the present case, the patient was locally prescribed ceftriaxone, which underscores the growing public health threat of antimicrobial resistance. To the best of our knowledge, this is the first report of ceftriaxone-induced AIN in pediatric age group.

Differentiating AIN from acute tubular injury (ATI) can sometimes be challenging for clinicians. Acute tubular injury may occur as a result of renal ischemia, sepsis, or nephrotoxicity. Prerenal cause such as dehydration may result in ischemic ATI. Furthermore, cephalosporins are known to cause nephrotoxicity.^{18,19} Urine analysis in AIN may show findings similar to that in ATI, such as RTECs, red cells, and casts. In such cases, renal biopsy remains to be the gold standard to establish the diagnosis of AIN. In the present case, dense interstitial infiltrate was seen accompanied by features of tubular injury.

Other less common causes of AIN should be considered particularly in the absence of drug exposure. Infections and systemic disorders including systemic lupus erythematosus (SLE), sarcoidosis, Sjogren's syndrome, tubulointerstitial nephritis and uveitis (TINU) syndrome, and antineutrophil cytoplasmic antibody (ANCA)-associated vasculitis may present with AIN. In the present case, there were no clinical features of SLE, dryness of mouth/eyes, or uveitis. ANA and ANCA serology was negative. Biopsy did not reveal granulomatous inflammation, ruling out sarcoidosis.

AKI has been reported in adults and less commonly in children with COVID-19 infection. In a recent study by

Stewart et al, out of 52 hospitalized pediatric patients, 46% were found to have elevated serum creatinine, and 29% had AKI (British Association for Pediatric Nephrology diagnostic criteria). Also, patients with AKI commonly had diarrhea and vomiting at presentation, indicating prerenal involvement.²⁰ Acute tubular necrosis, interstitial nephritis, microangiopathy and glomerulopathies have been reported in adults frequently requiring renal replacement therapy (RRT).²¹ Though in the present case, the patient had fever and diarrhea at initial presentation, there was no history of cough or respiratory symptoms and the patient tested negative for COVID-19.

To conclude, the diagnosis of AIN requires a high index of clinical suspicion with constellation of classical clinical findings and laboratory data. However, unusual findings such as an unremarkable urinalysis may be present in some cases and may pose a diagnostic challenge. Although, renal biopsy is required in most cases to confirm the diagnosis, urinalysis provides pertinent diagnostic clues in a backdrop of clinical and other laboratory parameters.

Authors' Contributions

R.K. and T.S. contributed to manuscript writing; G.B. and A.K. contributed to literature review, manuscript editing, clinical data acquisition; D.J. and S.M. contributed to manuscript review.

Conflict of Interest

None declared.

References

- Liaño F, Pascual J Madrid Acute Renal Failure Study Group. Epidemiology of acute renal failure: a prospective, multicenter, community-based study. *Kidney Int* 1996;50(03):811-818
- Perazella MA. Clinical approach to diagnosing acute and chronic tubulointerstitial disease. *Adv Chronic Kidney Dis* 2017;24(02):57-63
- Nussbaum EZ, Perazella MA. Diagnosing acute interstitial nephritis: considerations for clinicians. *Clin Kidney J* 2019;12(06):808-813
- Baldwin DS, Levine BB, McCluskey RT, Gallo GR. Renal failure and interstitial nephritis due to penicillin and methicillin. *N Engl J Med* 1968;279(23):1245-1252
- Rosert J. Drug-induced acute interstitial nephritis. *Kidney Int* 2001;60(02):804-817
- Nolan CR III, Anger MS, Kelleher SP. Eosinophiluria—a new method of detection and definition of the clinical spectrum. *N Engl J Med* 1986;315(24):1516-1519
- Fogazzi GB, Ferrari B, Garigali G, Simonini P, Consonni D. Urinary sediment findings in acute interstitial nephritis. *Am J Kidney Dis* 2012;60(02):330-332
- Moledina DG, Parikh CR. Differentiating acute interstitial nephritis from acute tubular injury: a challenge for clinicians. *Nephron* 2019;143(03):211-216
- Moledina DG, Perazella MA. Drug-induced acute interstitial nephritis. *Clin J Am Soc Nephrol* 2017;12(12):2046-2049
- Galpin JE, Shinaberger JH, Stanley TM, et al. Acute interstitial nephritis due to methicillin. *Am J Med* 1978;65(05):756-765
- Esteve JB, Launay-Vacher V, Brocheriou I, Grimaldi A, Izzedine H. COX-2 inhibitors and acute interstitial nephritis: case report and review of the literature. *Clin Nephrol* 2005;63(05):385-389

- 12 Mac K, Chavada R, Paull S, Howlin K, Wong J. Cefepime induced acute interstitial nephritis—a case report. *BMC Nephrol* 2015; 16:15
- 13 Plakogiannis R, Nogid A. Acute interstitial nephritis associated with coadministration of vancomycin and ceftriaxone: case series and review of the literature. *Pharmacotherapy* 2007;27(10): 1456–1461
- 14 Allon M, Lopez EJ, Min KW. Acute renal failure due to ciprofloxacin. *Arch Intern Med* 1990;150(10):2187–2189
- 15 Premalatha R, Phadke KD, Gag I, Rout P. Acute renal failure due to acute tubulointerstitial nephritis. *Indian Pediatr* 2003;40(04): 352–355
- 16 Printza N, Koukourgianni F, Saleh T, Goga C, Papachristou F. Drug-induced interstitial nephritis in a child with idiopathic nephrotic syndrome. *Saudi J Kidney Dis Transpl* 2009;20(06):1072–1075
- 17 Rhee C, Aol G, Ouma A, et al. Inappropriate use of antibiotics for childhood diarrhea case management - Kenya, 2009-2016. *BMC Public Health* 2019;19(03, Suppl 3):468
- 18 Barza M. The nephrotoxicity of cephalosporins: an overview. *J Infect Dis* 1978;137(Suppl):S60–S73
- 19 Longstreth KL, Robbins SD, Smavatkul C, Doe NS. Cephalexin-induced acute tubular necrosis. *Pharmacotherapy* 2004;24(06): 808–811
- 20 Stewart DJ, Hartley JC, Johnson M, Marks SD, du Pré P, Stojanovic J. Renal dysfunction in hospitalised children with COVID-19. *Lancet Child Adolesc Health* 2020;4(08):e28–e29
- 21 Battle D, Soler MJ, Sparks MA, et al; COVID-19 and ACE2 in Cardiovascular, Lung, and Kidney Working Group. Acute kidney injury in COVID-19: emerging evidence of a distinct pathophysiology. *J Am Soc Nephrol* 2020;31(07):1380–1383