

A Rare Case of Mycetoma Due to *Curvularia*

Rupali S Shinde, Sreedevi Hanumantha, Basappa G Mantur, Mahantesh V Parande

Department of Microbiology, Belagavi Institute of Medical Sciences, Belagavi, Karnataka, India

Address for correspondence: Dr. H Sreedevi, E-mail: svh105192119@gmail.com

ABSTRACT

Mycetoma due to *Curvularia* is a rare clinical entity. Here, we report a case of 27-year-old female presented with multiple swellings and discharging wounds around left shoulder joint since 12 years. Local examination showed diffuse nodular swellings over left anterior chest wall, posterior chest wall, and axilla. Multiple nodules and discharging sinuses were seen. Fungal culture of the biopsy of the lesion revealed *Curvularia* species. Patient showed significant clinical improvement with itraconazole therapy.

Key words: Culture, *Curvularia*, eumycetoma, sinus, swelling

INTRODUCTION

Mycetomas are chronic subcutaneous infections caused by fungi or actinomycetes, known as eumycetoma and actinomycetoma, respectively.^[1] It is usually posttraumatic, most commonly involves foot and rarely other body parts. It is mainly seen in Africa, India, Mexico, and South America. In India, actinomycetoma is prevalent in South, Southeast Rajasthan, and Chandigarh; while eumycetomas are common in North India.^[2] The most common agents of eumycetomas are *Madurella mycetomatis*, *Madurella grisea*, *Acremonium* spp. and *Fusarium* spp.^[3]

Here, we report a very rare case of Mycetoma occurred around the shoulder joint caused by *Curvularia*. To the best of our knowledge, only two reports of Mycetoma caused by *Curvularia* are reported till now.^[4,5] This requires special importance because of a rarity of causative agent and involvement of uncommon site.

CASE REPORT

A 27-year-old housewife, from a nearby village

presented to dermatology outpatient clinic of our hospital in March 2012 with complaints of multiple swellings and discharging wounds around the left shoulder joint since 12 years. She had taken treatment at multiple private hospitals without any relief and also etiological diagnosis. Patient did not remember any trauma to the particular part. Systemic examination did not reveal any abnormality. Local examination showed a diffuse nodular swelling located over left anterior chest wall, posterior chest wall and axilla. Multiple nodules and discharging sinuses were seen [Figure 1]. The discharge was seropurulent, and no granules were detected. Few sinuses were found healed with scarring. The skin over the area was hyperpigmented and thickened. There was no regional lymph node involvement.

All routine investigations including hematological, biochemical, and radiological tests were within normal limits. Pus samples from discharging sinuses were sent for microbiological investigation. Furthermore, multiple tissue biopsies were sent for histopathology and for bacterial and fungal culture. Gram stain of the pus sample showed plenty of pus cells along with Gram-positive cocci in clusters. Bacteriological culture yielded *Staphylococcus aureus* in pure culture. This was considered as a probable case of botryomycosis and was started on antibiotic therapy. There was no significant improvement in discharge. Multiple tissue fragments were cultured on Sabouraud's dextrose agar both with and without antibiotics and were incubated at room temperature and at 37°C. Fungal culture of multiple

Access this article online	
Quick Response Code: 	Website: www.jlponline.org
	DOI: 10.4103/0974-2727.154799

biopsies isolated black colored colonies after 1-week of incubation. Colonies were having black reverse and white aerial hyphae [Figure 2]. Microscopically, the lactophenol cotton blue preparation revealed septate, unbranched, brown-colored conidiophores along with conidia. The conidia were large, brown in color, with swollen subterminal cell, usually four-celled with three septa [Figure 3]. The isolate was identified as *Curvularia* species. Similarly, tissue biopsy showed basophilic centers and a dark periphery showing mycelia along with neutrophilic infiltrate. Patient was identified as a case of eumycotic Mycetoma considering laboratory confirmation and also the duration of the disease and nonresponsiveness to antibiotics. Patient was started on itraconazole 100 mg twice a day and responded well to the therapy with reduction of swelling and sinuses.

DISCUSSION

Mycetoma is a chronic slowly progressive, posttraumatic infection of subcutaneous tissue, usually involving foot. It is characterized by swelling, draining sinuses, and discharge of grains. Mycetoma caused by true fungi has been encountered less frequently as compared with those caused by actinomycetes. There are various etiological agents of eumycetoma, commoner ones are *M. mycetomatis*, *M. grisea*, *Acremonium* spp. and *Fusarium* spp. *Curvularia* causing mycetoma is very rare, and only a few cases have been reported.^[2-5]

Curvularia is a dematiaceous fungus that is ubiquitous among soil and vegetation in temperate areas. There are 31 species, and most commonly recovered in man has been *Curvularia lunata*, followed by *Curvularia geniculata*.^[1] Originally thought to be solely a pathogen of plants but in the last centuries it is encountered in human infections also. *Curvularia* can cause ocular, respiratory, cerebral infections, and Mycetoma.

In the present case, there is an unusual site involvement. Here, lesions were present around the joint. Infection could be due to carrying wooden splint on head and shoulder joint which is a common practice in rural India.

Identification of causative agents of Mycetoma is very essential for proper and effective management of it as eumycetoma should be treated with adequate antifungal therapy and surgery whereas actinomycetoma responds well to antibacterial therapy. Currently, itraconazole and ketoconazole are the treatment options used for eumycetoma. This patient had lesions around shoulder joint hence was

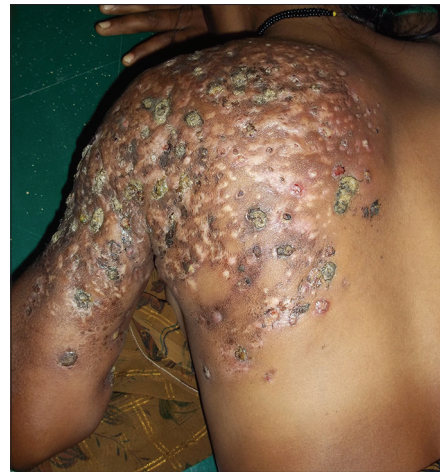

Figure 1: Multiple nodules and discharging sinuses around the left shoulder joint

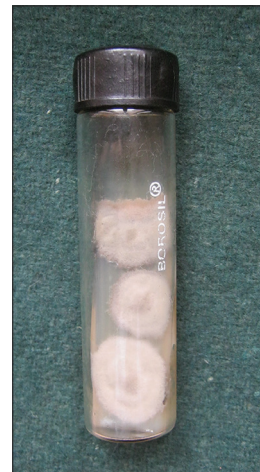

Figure 2: Fungal colonies with white aerial hyphae and black reverse

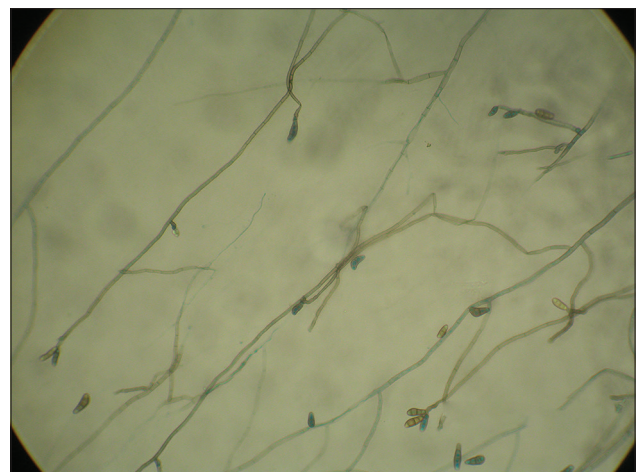


Figure 3: Lactophenol cotton blue mount showing septate, unbranched, brown-colored conidiophores with large, brown conidia 3-4 septa

difficult for surgical therapy and was started on itraconazole. Within 3 months, the patient showed significant improvement

in terms of reduction of discharging sinuses, nodules and healing by scarring.

To conclude, it is very important to determine the causative agent in every patient suspected of Mycetoma to establish an adequate and timely plan to avoid persistence and dissemination of the disease.

REFERENCES

1. Hay RJ. Agents of eumycotic Mycetomas. Topley and Wilsons Textbook of

- Microbiology. 10th ed., Vol. 4. London: Hodder Arnold Ltd.; 2005. p. 487-96.
2. Chakraborti A, Singh K. Mycetoma in Chandigarh and surrounding areas. Indian J Med Microbiol 1998;16:64-5.
3. Rippon JW. The pathogenic fungi and pathogenic actinomycetes. Medical Mycology. 3rd ed. London: WB Saunders; 1998. p. 80-118.
4. Garg A, Sujatha S, Garg J, Parija SC, Thappa DM. Eumycetoma due to *Curvularia lunata*. Indian J Dermatol Venereol Leprol 2008;74:515-6.
5. Janaki C, Sentamilselvi G, Janaki VR, Devesh S, Ajithados K. Case report. Eumycetoma due to *Curvularia lunata*. Mycoses 1999;42:345-6.

How to cite this article: Shinde RS, Hanumantha S, Mantur BG, Parande MV. A rare case of mycetoma due to *Curvularia*. J Lab Physicians 2015;7:55-7.

Source of Support: Nil. **Conflict of Interest:** None declared.

New features on the journal's website

Optimized content for mobile and hand-held devices

HTML pages have been optimized for mobile and other hand-held devices (such as iPad, Kindle, iPod) for faster browsing speed.

Click on [**Mobile Full text**] from Table of Contents page.

This is simple HTML version for faster download on mobiles (if viewed on desktop, it will be automatically redirected to full HTML version)

E-Pub for hand-held devices

EPUB is an open e-book standard recommended by The International Digital Publishing Forum which is designed for reflowable content i.e. the text display can be optimized for a particular display device.


Click on [**EPub**] from Table of Contents page.

There are various e-Pub readers such as for Windows: Digital Editions, OS X: Calibre/Bookworm, iPhone/iPod Touch/iPad: Stanza, and Linux: Calibre/Bookworm.

E-Book for desktop

One can also see the entire issue as printed here in a 'flip book' version on desktops.

Links are available from Current Issue as well as Archives pages.

Click on  View as eBook