



Cystic Pancreatic Neuroendocrine Tumor: A Diagnostic Dilemma

Md Ali Osama¹ Meera Mathayoth² Shilpi Agarwal¹ Priti Chatterjee¹

¹Department of Pathology, Lady Hardinge Medical College, New Delhi, India

²Department of Pathology, Amrita Institute of Medical Sciences, Kochi, Kerala, India

Address for correspondence Priti Chatterjee, MD, Department of Pathology, Lady Hardinge Medical College, New Delhi, 110001, India (e-mail: doctorpriti@gmail.com).

J Lab Physicians 2023;15:159–161.

Abstract

Keywords

- ▶ cystic lesion
- ▶ chromogranin
- ▶ neuroendocrine tumor
- ▶ pancreas
- ▶ synaptophysin

Pancreatic neuroendocrine tumors are typically solid neoplasms but in rare instances may present as cystic lesions. Preoperative diagnosis of a cystic pancreatic lesion is challenging and requires a multidisciplinary and multimodal approach. We hereby describe an elderly female who came with complaints of abdominal lump. Radiologically, it appeared to be a pancreatic hydatid cyst located at the head of the pancreas, following which resection was done. Histopathological study of the lesion turned out to be a cystic pancreatic neuroendocrine tumor. Thus, we present this unique case due to its rarity and diagnostic challenge.

Introduction

Pancreatic neuroendocrine tumors (PanNETs) are rare neoplasms that constitute less than 3% of pancreatic malignancies with an annual prevalence of 0.8 per million people.¹ PanNETs show primarily solid tumor morphology, however, cystic presentation can occur. PanNETs are seen in the 6th or 7th decade of life with a relative equal sex distribution. Cystic PanNETs are typically sporadic, most of them being solitary and nonfunctional. Preoperative diagnosis is often challenging, as they are incidentally discovered. Cystic PanNETs often mimic other pancreatic cystic neoplasms on radiological examination, hence, histopathological examination is required for the correct diagnosis.

Case Report

A 65-year-old female presented with an abdominal mass for the past 2 years which was progressively increasing in size. She had no fever, chills, jaundice, excessive sweating, or

diarrhea. Ultrasonography (USG) revealed a well-defined hypoechoic lesion in the head of the pancreas measuring 7 × 8 × 3 cm which was predominantly cystic. The cystic lesion raised a suspicion of hydatid cyst radiologically. The patient had a course of albendazole from another hospital due to a similar suspicion of hydatid cyst. However, the size of the abdominal lump continued to persist and hence the patient was referred to the surgery outpatient department in our hospital. Laboratory investigations were within normal limits. USG findings were reconfirmed and a differential diagnosis of pancreatic cystic mucinous neoplasm or hydatid cyst was made. No preoperative aspiration cytology was done. Intraoperatively, a well-circumscribed cystic lesion measuring 8 × 8 × 7 cm was identified in the head of pancreas. Enucleation of the lesion was performed and the specimen was sent for histopathological examination. Grossly, the tumor had a predominantly cystic appearance and measured 8 × 8 × 5 cm with few solid areas attached to the wall of the cyst. Part of normal pancreatic parenchyma was identified at the periphery. The cyst was unilocular and thin-walled with

article published online
July 26, 2022

DOI <https://doi.org/10.1055/s-0042-1750079>.
ISSN 0974-2727.

© 2022. The Indian Association of Laboratory Physicians. All rights reserved.

This is an open access article published by Thieme under the terms of the Creative Commons Attribution-NonDerivative-NonCommercial-License, permitting copying and reproduction so long as the original work is given appropriate credit. Contents may not be used for commercial purposes, or adapted, remixed, transformed or built upon. (<https://creativecommons.org/licenses/by-nc-nd/4.0/>)

Thieme Medical and Scientific Publishers Pvt. Ltd., A-12, 2nd Floor, Sector 2, Noida-201301 UP, India

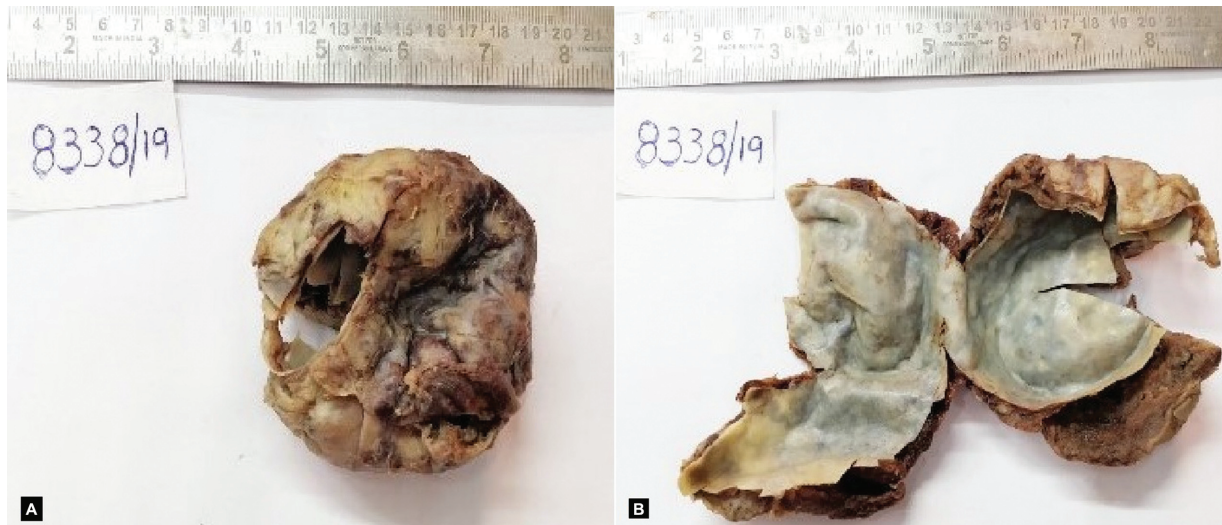

Fig. 1 (A) Gross image of solid-cystic pancreatic mass with a single central unilocular cyst; (B) gross image of opened cyst with a smooth and shiny internal surface.

a smooth shiny internal surface (→**Fig. 1A, B**). The cyst fluid appeared clear. On microscopic examination, a well-circumscribed, encapsulated tumor was seen with a rim of normal pancreatic parenchyma at the periphery (→**Fig. 2A**). A central cystic area delineated by fibrocollagenous tissue separated the cyst from the layer of neoplastic cells (→**Fig. 2B, C**). No definite lining epithelium of the cyst was identified. The solid part of the tumor was composed of sheets of monotonous population of medium-sized polygonal cells with finely granular eosinophilic cytoplasm. Delicate vascular channels were interspersed between the tumor cells. The nuclei were

centrally placed, round to ovoid in shape with finely stippled chromatin (salt and pepper) (→**Fig. 2D**). Mitotic figures were rare. The tumor cells were immunohistochemically positive for chromogranin (→**Fig. 2E**), synaptophysin, and neuron-specific enolase, and were negative for vimentin, β -catenin, and cytokeratin. The Ki-67 index was low ($< 3\%$) (→**Fig. 2F**). Based on the histomorphological features and immunohistochemistry, a diagnosis of cystic well-differentiated PanNET (low grade [G1]) was made. The patient had an uneventful postoperative period and showed no signs of recurrence or metastasis in 2 years of follow-up.

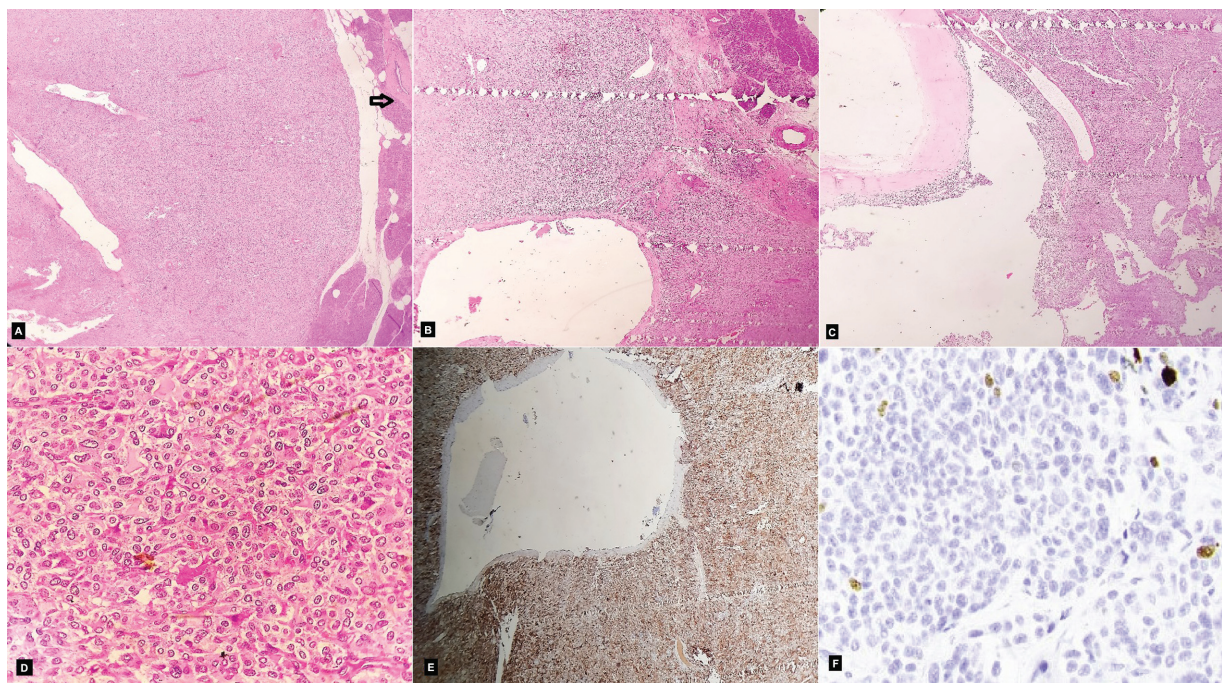


Fig. 2 (A) Well-circumscribed, encapsulated tumor with rim of normal pancreatic parenchyma at the periphery (arrow) (H&E 100 \times); (B, C) central cystic area delineated by fibrocollagenous tissue from the layer of neoplastic cells arranged in sheets (H&E 100 \times); (D) cellular tumor composed of monotonous population of medium-sized polygonal cells (H&E 200 \times); (E) IHC staining: synaptophysin positive (100 \times); (F) IHC staining: low Ki67 proliferative index (200 \times). IHC, immunohistochemistry.

Discussion

Cystic PanNET is considered to be an uncommon entity and is thought to occur as a result of tumor necrosis, ischemia, or degeneration within a solid PanNET. Buetow et al in their study demonstrated a relationship between tumor size and consistency; 27 out of 36 islet cell tumors showed cystic change (mean diameter: 7.7 cm).² Kamisawa et al proposed that PanNETs are slow-growing tumors and in course of time they develop a fibrous capsule, hampering the blood supply to the tumor, resulting in infarction and necrosis leading to a cystic appearance.³ Iacono et al suggested that hemorrhage is the initial event in the development of the tumor's cystic form.⁴ Cystic PanNETs are more commonly located in the neck, body, or tail of the pancreas than in the head or uncinete process compared with the solid counterparts.⁵ On the contrary, the present case showed a lesion in the head of pancreas. In the published literature, there are reports suggesting cystic PanNETs as a distinct entity rather than a variant. Cystic PanNETs are believed to be of a lower grade, less aggressive with a presentation at a lower stage than the solid counterparts.^{6,7} In a study of 106 PanNET cases by Khalil et al, no recurrence or metastasis was noted in all 22 cystic PanNETs.⁸ Koh et al in their study concluded that the incidence of regional lymph node metastases with cystic PanNETs is less as compared with solid PanNETs.⁹ Preoperative radiological diagnosis of cystic PanNETs remains to be a diagnostic challenge and they are often misdiagnosed.¹⁰ The primary difficulty while imaging is distinguishing cystic PanNETs from other entities like simple cysts, pseudocysts, and cystic neoplasms of the pancreas such as intraductal papillary mucinous neoplasm, mucinous cystic neoplasm, or adenocarcinoma with cystic degeneration. Distinction of the cystic pancreatic lesions having malignant potential from those lesions with a benign clinical outcome is important for the correct therapy. Ligneau et al proposed that cystic PanNETs should be treated with surgical resection due to their possible malignant progression.¹¹ However, Cloyd et al concluded that pure cystic PanNETs represent a subgroup that could be monitored clinically and radiologically without immediate resection, given their benign progression.¹² Complete resection is the treatment of choice for cystic PanNET along with close follow-up to avoid chances of recurrence or metastasis.

Conclusion

Cystic PanNETs are a distinctive entity in PanNETs with specific clinical and pathologic features. Because of their cystic nature, these often cause a diagnostic dilemma to the radiologist as seen in the present case. The histomorphological features and immunohistochemical study aid in diagnosis of cystic PanNETs. Cystic PanNETs tend to be less

aggressive than their solid counterparts indicating a better prognosis and survival in this group of patients.

Patient Consent

The authors certify that they have obtained the appropriate consent from the parent. The patient has given his consent for the images and other clinical information to be reported in the journal. The parent understands that the name and initials will not be published, and due efforts have been made to conceal the same.

Funding

None.

Conflict of Interest

None declared.

References

- 1 Dasari A, Shen C, Halperin D, et al. Trends in the incidence, prevalence, and survival outcomes in patients with neuroendocrine tumors in the United States. *JAMA Oncol* 2017;3(10):1335–1342
- 2 Buetow PC, Parrino TV, Buck JL, et al. Islet cell tumors of the pancreas: pathologic-imaging correlation among size, necrosis and cysts, calcification, malignant behavior, and functional status. *AJR Am J Roentgenol* 1995;165(05):1175–1179
- 3 Kamisawa T, Fukayama M, Koike M, Tabata I, Okamoto A. A case of malignant cystic endocrine tumor of the pancreas. *Am J Gastroenterol* 1987;82(01):86–89
- 4 Iacono C, Serio G, Fugazzola C, et al. Cystic islet cell tumors of the pancreas. A clinico-pathological report of two nonfunctioning cases and review of the literature. *Int J Pancreatol* 1992;11(03):199–208
- 5 Kawamoto S, Johnson PT, Shi C, et al. Pancreatic neuroendocrine tumor with cystlike changes: evaluation with MDCT. *AJR Am J Roentgenol* 2013;200(03):W283–90
- 6 Singhi AD, Chu LC, Tatsas AD, et al. Cystic pancreatic neuroendocrine tumors: a clinicopathologic study. *Am J Surg Pathol* 2012;36(11):1666–1673
- 7 Nakashima Y, Ohtsuka T, Nakamura S, et al. Clinicopathological characteristics of non-functioning cystic pancreatic neuroendocrine tumors. *Pancreatol* 2019;19(01):50–56
- 8 Khalil A, Ewald J, Marchese U, et al. A single-center experience with pancreatic cystic neuroendocrine tumors. *World J Surg Oncol* 2020;18(01):208
- 9 Koh YX, Chok AY, Zheng HL, Tan CS, Goh BK. A systematic review and meta-analysis of the clinicopathologic characteristics of cystic versus solid pancreatic neuroendocrine neoplasms. *Surgery* 2014;156(01):83–96.e2
- 10 Caglià P, Cannizzaro MT, Tracia A, et al. Cystic pancreatic neuroendocrine tumors: to date a diagnostic challenge. *Int J Surg* 2015; 21(Suppl 1):S44–S49
- 11 Ligneau B, Lombard-Bohas C, Partensky C, et al. Cystic endocrine tumors of the pancreas: clinical, radiologic, and histopathologic features in 13 cases. *Am J Surg Pathol* 2001;25(06):752–760
- 12 Cloyd JM, Kopecky KE, Norton JA, et al. Neuroendocrine tumors of the pancreas: degree of cystic component predicts prognosis. *Surgery* 2016;160(03):708–713