

Case Report

Liver and mesenteric hydatid cyst in a child

Sravanthi Vutukuru¹, Nitin James Peters¹, Abhishek Mewara², Simran Kaur¹, Ram Samujh¹

¹Department of Pediatric Surgery, Postgraduate Institute of Medical Education and Research, Chandigarh, India, ²Department of Medical Parasitology, Postgraduate Institute of Medical Education and Research, Chandigarh, India.

*Corresponding author:

Nitin James Peters, MS, Mch (Pediatric Surgery), Department of Paediatric Surgery, Postgraduate Institute of Medical Education and Research, Chandigarh 160012, India.

nitinjamespeters@yahoo.com;
p.nitinjames@pgimer.edu.in

Received: 14 January 2023
Accepted: 05 August 2023
Epub Ahead of Print: 13 September 2023
Published: 08 June 2024

DOI

10.1055/s-0043-1774379

Quick Response Code:



This article was published by Thieme Medical and Scientific Publishers Pvt. Ltd. as online first

ABSTRACT

Hydatid disease, though endemic in the sub-Himalayan region of the subcontinent, is relatively rare in the pediatric age group. The simultaneous existence of hydatid in two or more organs is very rare, seen only in 5 to 13% of patients. We report an 11-year-old patient, who presented with painless progressive abdomen distension over 6 months. Imaging studies revealed a large cystic lesion occupying majority of the abdomen. The patient was diagnosed to have a hydatid cyst of the liver and mesentery, with multiple daughter cysts intraoperatively. Excision of the cyst was done and the patient is doing well on postoperative follow-up of 1 year.

Keywords: abdominal cysts, hepatic hydatid, mesenteric hydatid cysts, multiple hydatids

INTRODUCTION

Hydatid disease is relatively uncommon in the pediatric age group.^[1] The lung and liver are the usual organs involved.^[2] Patients are usually asymptomatic until the cyst grows large enough to cause compression on the adjacent organs and cause symptoms. Pressure effects are initially vague and include nonspecific pain, cough, low-grade fever, and the sensation of abdominal fullness. Often, two or more organs can be involved. It has varied presentations and can mimic intra-abdominal cystic lesions or lymphangioma. We report a case of unusual presentation of hydatid, involving the liver and mesentery in a child.

CASE REPORT

An 11-year-old female child presented, with painless progressive abdomen distension for the past 6 months, associated with loss of appetite. There was no history of constipation, jaundice, hematemesis, cough, breathlessness, burning micturition, or increase in the frequency of micturition. There was a history of cattle rearing in their house. The family relied on a portable water source. On examination, the general condition was fair, with no pallor. Per abdominal examination revealed a 10*8 cm cystic mobile, nontender mass occupying the entire right hypochondrium, right lumbar, and epigastrium. Routine hematological investigations were normal with no eosinophilia and hydatid serology was nonreactive. Ultrasonography of the abdomen was suggestive of a multiloculated, cystic swelling extending from the epigastrium to the pelvis and contrast-enhanced computed tomography (CT) of the abdomen showed a huge hypodense, homogenous cystic lesion with multiple septations, without any calcifications,

This is an open-access article distributed under the terms of the Creative Commons Attribution-Non Commercial-Share Alike 4.0 License, which allows others to remix, transform, and build upon the work non-commercially, as long as the author is credited and the new creations are licensed under the identical terms.

©2024 Published by Indian Association of Laboratory Physicians

occupying the entire right side of the abdomen from the liver to the pelvis, pushing the small intestines to the left. The working diagnosis of mesenteric lymphangioma was entertained and, the child was taken up for exploratory midline laparotomy.

Intraoperatively, a large cyst occupying almost the whole of the abdomen, extending from the right hypochondrium to the hypogastrium, was noted. It was identified to be arising from the undersurface of segment 5 of the liver and densely adherent to the mesentery, displacing the entire small bowel to the left. The cyst had two separate “Cyst-pods” one arising from the liver and the other from the base of the mesentery. Multiple daughter cysts were seen inside the cyst (Figure 1A–C). The entire cyst was removed in toto without any spill, leaving a small cavity of size 3 × 5 cms in the liver parenchyma. Histopathology examination revealed multiple hooklets, confirming hydatid disease (Figure 2). Postoperatively, the child was stable and was orally allowed on postoperative day (POD)-2. The patient was discharged on POD-4 after drain removal and was started on tab albendazole (10 mg/kg/day) for 3 months. At 1-year follow-up, the patient is doing well and has no recurrence.

DISCUSSION

Hydatid disease or hydatidosis, caused by *Echinococcus granulosus*, is endemic in the Indian subcontinent, especially in the sub-Himalayan regions.^[3,4] Exposure to pets, lack of proper hand hygiene, scarcity of water, and farming are risk factors of hydatid disease.^[5,6] Lung hydatids are more common than the liver in the pediatric age group, contrary to adults.^[1] In nearly 8 to 10% of the patients, hydatid cysts can be present in unusual locations like peritoneum, mesentery, and omentum.^[2,7,8] Intraperitoneal hydatid disease is seen in approximately 3.9 to 12.5% of patients.^[9,10] The involvement of two organs is seen in 5 to 13% of the patients.^[11] Patients with hydatid disease may remain asymptomatic for a long period of time until the cyst is large enough to cause symptoms.^[12] Hydatid cysts usually present as well-defined thick-walled

cystic lesions with daughter cysts. The index case had a flimsy cyst wall contrary to the usually reported intraoperative findings. Prompt treatment of these cysts is recommended as they are prone to complications like rupture, hemorrhage, infection, torsion, and dissemination of the disease.^[13] Recurrence due to spillage has been reported in up to 13% of patients.^[14] Hydatid cyst can be considered in the differential diagnosis of large intra-abdominal cysts like a mesenteric, omental, or duplication cyst. Mesenteric lymphangioma is also an important differential diagnosis to be considered.

A search of the PubMed and Embase databases using the following search terms: (“liver” OR “hepatic”) AND (“mesenteric” OR “mesentery”) AND (“hydatid” OR “hydatidosis” OR “echinococcus”) yielded no such similar case in the pediatric age group. However, the simultaneous occurrence of hepatic and mesenteric hydatid was seen in a 39 year old young man as reported by Paramythiotis et al.^[15] The presentation was similar to our index case and the CT imaging revealed three calcified lesions, one in the liver, one adjacent to an ileal loop, and one close to the urinary bladder. Excision of the lesions was done.

Another report by Deshmukh et al^[16] revealed multiple hydatids in the liver, mesentery, peritoneum in a 61-year-old female who presented with abdomen distension. Laparotomy and excision of the cysts have been done. In literature, there have been many case reports and series on multiple hydatids of the lung, liver, spleen, peritoneal cavity, etc., but the presence of isolated liver and mesenteric hydatid is very rare. We hypothesize that involvement of the mesentery could be attributed to an event of a subclinical rupture from the liver cyst and intraperitoneal seeding of daughter cysts or escape into the systemic circulation.^[17,18] Fortunately, the index case did not develop anaphylaxis and the cyst size gradually progressed causing the symptoms as described.

The goal of treatment in hydatid disease is to prevent rupture and spillage of the hydatid. Depending on Gharbi’s classification, the management of the cyst changes. Surgical treatment is required in Gharbi type 3 and 4 lesions, and open

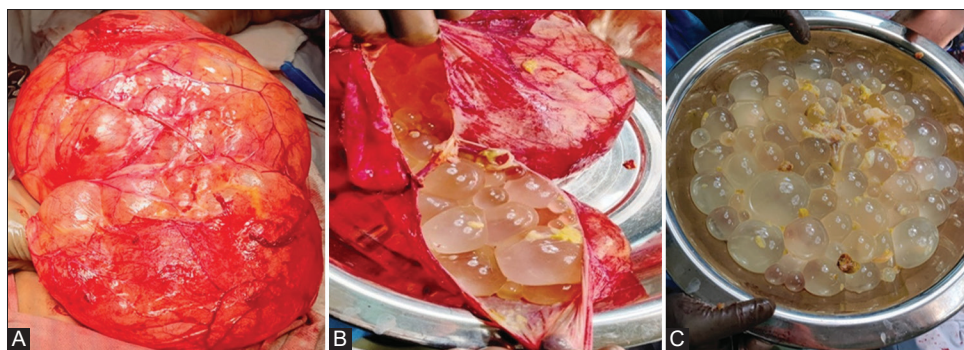


Figure 1: (A) Intraoperative picture of a large thin-walled cyst, (B) multiple daughter cyst inside the cyst, (C) daughter cyst delivered out.

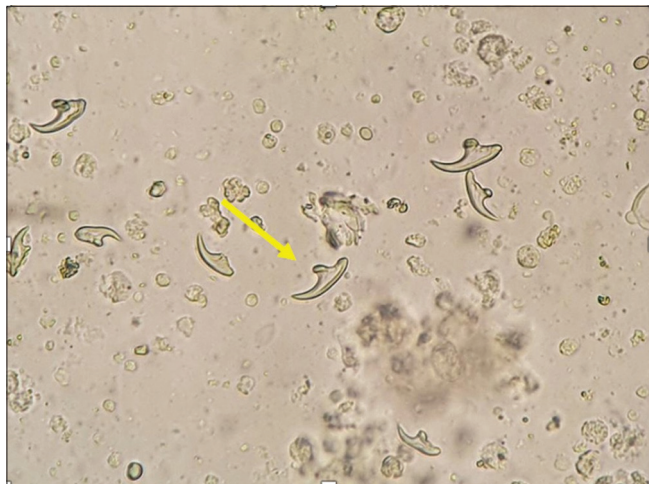

Figure 2: Photomicrograph (Wet mount microscopy) showing several hooklets (yellow arrow) of *Echinococcus granulosus*.

surgery is required in lesions more than 14cm in size.^[16,19] However, percutaneous treatment is done in Gharbi type 1 and 2 and no treatment is required in Gharbi type 5. Appropriate scolical agents, like 10% povidone-iodine or 3% hypertonic saline, must be used during surgery to prevent anaphylaxis and distant seeding of the disease. Gentle and meticulous dissection is imperative with complete excision where ever possible. Postoperatively, the patients are treated with albendazole (dose: 10 mg/kg/day) for 3 months to prevent a recurrence.^[16,19,20]

CONCLUSIONS

Involvement of liver and mesentery with hydatid disease is very rare. In the pediatric age group, trivial trauma while playing can lead to rupture of the cyst and cause the spread of the disease. Mesenteric hydatid cysts present with vague symptoms similar to mesenteric cysts. They should be kept as one of the differential diagnoses, especially in endemic regions. Appropriate management will prevent infection and rupture of the cyst, which can be life-threatening.

Conflict of Interest

None declared.

REFERENCES

1. Mishra A, Patel K. Hydatid disease in children: a single centre study with analysis of treatment protocol. *Int Surg J* 2020;7:6
2. Geramizadeh B. Unusual locations of the hydatid cyst: a review from Iran. *Iran J Med Sci* 2013;38:2–14

3. De U. Primary abdominal hydatid cyst presenting in emergency as appendicular mass: a case report. *World J Emerg Surg* 2009;4:13
4. Geramizadeh B. Isolated peritoneal, mesenteric, and omental hydatid cyst: a clinicopathologic narrative review. *Iran J Med Sci* 2017;42:517–523
5. Moroni S, Moscatelli G, Bournissen FG, et al. Abdominal cystic echinococcosis treated with albendazole. a pediatric cohort study. *PLoS One* 2016;11:e0160472
6. Gupta R, Sharma SB, Prabhakar G, Mathur P. Hydatid disease in children: our experience. *Formos J Surg* 2014;47: 211–220
7. Gossios KJ, Kontoyiannis DS, Dascalogiannaki M, Gourtsoyiannis NC. Uncommon locations of hydatid disease: CT appearances. *Eur Radiol* 1997;7:1303–1308
8. Mushtaque M, Mir MF, Malik AA, Arif SH, Khanday SA, Dar RA. Atypical localizations of hydatid disease: experience from a single institute. *Niger J Surg* 2012;18:2–7
9. Sable S, Mehta J, Yadav S, Jategaokar P, Haldar PJ. “Primary omental hydatid cyst”: a rare entity. *Case Rep Surg* 2012; 2012:654282
10. Sekmenli T, Koplay M, Sezgin A. Isolated omental hydatid cyst: clinical, radiologic, and pathologic findings. *J Pediatr Surg* 2009; 44:1041–1043
11. Kushwaha JK, Gupta R, Mohanti S, Kumar S. Primary mesenteric hydatid cyst. *BMJ Case Rep* 2012;2012:bcr0320125996
12. Mehra BR, Thawait AP, Gupta DO, Narang RR. Giant abdominal hydatid cyst masquerading as ovarian malignancy. *Singapore Med J* 2007;48:e284–e286
13. Toumi O, Noomen F, Salem R, et al. Intraperitoneal rupture of hydatid cysts. *Eur J Trauma Emerg Surg* 2017;43:387–391
14. Mouaqit O, Hibatallah A, Oussaden A, Maazaz K, Taleb KA. Acute intraperitoneal rupture of hydatid cysts: a surgical experience with 14 cases. *World J Emerg Surg* 2013;8:28
15. Paramythiotis D, Karakatsanis A, Bangeas P, et al. Simultaneous hepatic and mesenteric hydatid disease-a case report. *Front Surg* 2017;4:64
16. Deshmukh S, Fulare S, Chowksey S, Kate R. Hydatidosis: case report and literature review. *Indian J Case Rep* 2020;6: 185–187
17. Sayarlioglu H, Erkok R, Soyoral Y, Etlik O, Dogan E, Kotan C. Peritoneal hydatid cyst: an unusual cause of abdominal pain in a haemodialysis patient. *Nephrol Dial Transplant* 2006;21: 1441–1442
18. Rathod KJ, Lyndogh S, Kanojia RP, Rao KL. Multiple primary omental hydatid: rare site for a common infestation. *Trop Gastroenterol* 2011;32:134–136
19. Bayrak M, Altintas Y. Current approaches in the surgical treatment of liver hydatid disease: single center experience. *BMC Surg* 2019; 19:95
20. Wani RA, Malik AA, Chowdri NA, Wani KA, Naqash SH. Primary extrahepatic abdominal hydatidosis. *Int J Surg* 2005;3: 125–127

How to cite this article: Vutukuru S, Peters NJ, Mewara A, Kaur S, Samujh R. Liver and mesenteric hydatid cyst in a child. *J Lab Physicians*. 2024;16:207-9. doi: 10.1055/s-0043-1774379