

Actinomycetes Mycetoma

Sumati Hogade, Metgud S C, Swooroparani

Department of Microbiology, J. N. Medical College, Belgaum, Karnataka, India

Address for correspondence: Dr. Sumati Hogade, E-mail: sumatihogade@yahoo.co.in

ABSTRACT

Mycetoma is a chronic infection, frequently seen in tropical and sub-tropical countries and is considered as an occupational disease. Nocardia species though it can infect immunocompetent individuals, it most commonly affects immunocompromised patients. A 50-year-old male, farmer presented to our hospital with serosanguineous discharging swelling over the dorsum of right foot. We have isolated *Nocardia asteroides* from the tissue sample. Speciation of this isolate was carried out based on phenotypic methods. Hereby we report a case of Actinomycetes Mycetoma in an immunocompetent individual.

Keywords: Mycetoma, nocardia, subcutaneous

INTRODUCTION

Nocardiosis is a localized or disseminated infection caused by the aerobic filamentous bacteria belonging to the genus *Nocardia*. Although *Nocardia* species can infect immunocompetent individuals, it most often infects immunocompromised patients. The actinomyces species are normally present in the mouth, intestine and vagina as commensals; whereas, *Nocardia* species are inhabitants of soil. Trauma foreign bodies or poor oral hygiene may favor tissue invasion. Patients at risk of acquiring this infection include those undergoing immunosuppressive corticosteroids therapy, chemotherapy, organ transplant recipients, tuberculosis, acquired immunodeficiency syndrome, diabetes mellitus and alcoholism. The infection may be self-limiting or may progress to an acute, sub-acute or chronic disease involving lungs, brain and subcutaneous tissue.

Mycetoma is a chronic infection, frequently seen in tropical and sub-tropical countries and is

considered as an occupational disease. Clinically, Mycetoma is characterized by swelling, formation of sinuses and alteration of the affected region. It occurs most commonly in limbs, appears subcutaneously and spreads easily to the bones and viscera. Here we report a case of sub-cutaneous Nocardiosis of right foot due to *N. asteroides* in an immunocompetent individual.

CASE REPORT

A 50-year-old farmer presented to us with fever and serosanguineous discharging swelling over the dorsum of right foot. To start with the growth was small, approximately 1-2 cm in size and without any pain and discharge. Over the last 18 months, it has progressed gradually and occupied the whole of the dorsum of right foot. Past history was nothing significant, no history of trauma or injury to the foot, non-diabetic, non-hypertensive and not suffering from tuberculosis. But 3 months back at the local hospital the patient was diagnosed as having tuberculosis and treated with anti-tubercular drugs. However, there was no improvement even after 2 months of treatment, hence discontinued the treatment. Local examination revealed a grossly swollen entire dorsum of the right foot with intense erythema, numerous elevated, well-demarcated small to large nodular lesions with few discharging sinuses. Sinus openings were inflamed and mostly blocked with dried pus. The foot was

Access this article online	
Quick Response Code: 	Website: www.jlponline.org
	DOI: 10.4103/0974-2727.78564

grossly deformed, and it was tender. Veins of the right leg were dilated and pitting edema extended almost up to the knee. Discharge was yellowish, purulent and foul smelling without any apparent granules [Figure 1]. Pus was collected in a sterile bottle by aspirating with sterile Pasteur pipette. A piece of biopsy 4 × 6 mm was obtained from one of the nodular swellings and subjected for microbiological and histopathological examination.

A thorough physical examination revealed no other abnormality except that the patient had mild fever. His hemoglobin was 10 g/dl, total leucocyte count was 11,900/mm³, polymorphonuclear leucocytes 80%, ESR 40 mm/h [Westergren's method]. HIV seronegative, LFT, RFT and electrolytes were within normal limits. There is no evidence of any other disease or abnormality.

The radiological examination of antero-posterior and lateral view of right foot showed soft tissue density occupying the inter-pharyngeal and metatarsal joint space causing spreading of 2nd and 3rd inter-pharyngeal joint space and there was no bone involvement.

In the laboratory, a smear was prepared from the sample and stained with Gram's stain, which revealed thin, long, branching, Gram-positive filamentous bacilli [Figure 2]. On modified Ziehl-Neilson stain (1% H₂SO₄ decolorizer) the filaments were weakly acid fast.

Culture was done on sheep blood agar and Sabouraud's dextrose agar (SDA) with antibiotics. A small, dry, granular, wrinkled chalky white to cream colored colonies were grown after a week's incubation at 37°C. The colonies were identified as *Nocardia* species by culture smear and were subjected for biochemical testing for confirmation and speciation. The colonies were inoculated onto different decomposition media like urease, casein, xanthine, and hypoxanthine to see the hydrolysis of media. These differential plates were incubated at 30°C for 3 weeks. As per the morphological, cultural and biochemical characteristics the isolates was identified as *N. asteroides*.

The histopathological examination of biopsy revealed structure of skin, sub-cutaneous tissue and sinus tract lined by granulation tissue. Few irregular lobulated light basophilic granules were present. The granules are not bordered at the periphery by the eosinophilic material; the filaments in the granules are weak acid fast giving an impression of multiple discharging sinuses of foot – Actinomycetes Mycetoma – *Nocardia* species.

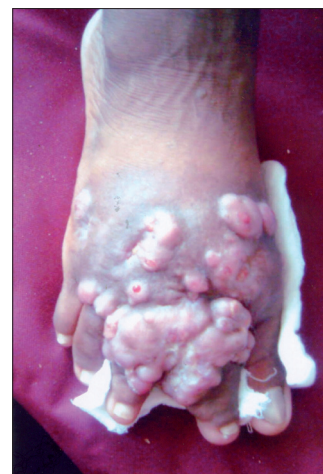

Figure 1: Photograph of lesion

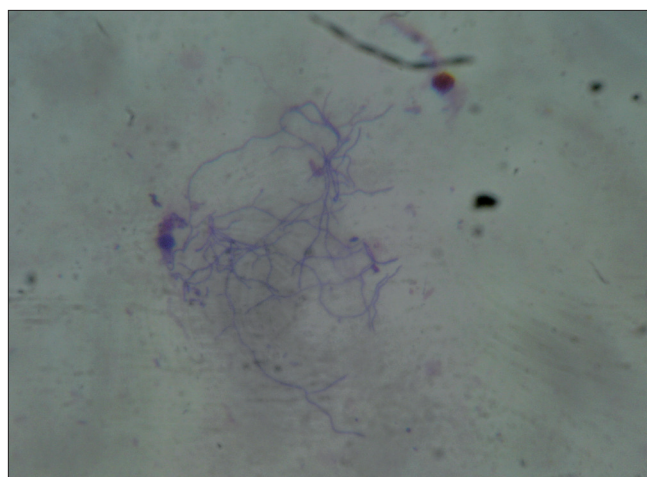


Figure 2: Direct smear from the discharge

The patient showed dramatic improvement with Minocycline, Dapsone, and Amikacin in cycles of 5 weeks followed by an additional course of Ciprofloxacin. After 6 months of treatment, the lesion healed with significant scarring.

DISCUSSION

Nocardial infections occur worldwide, particularly in tropical and subtropical areas. Actinomycetoma is more often seen in sub-tropical areas, particularly in America (Mexico and Venezuela), whereas Eumycetoma predominates in Africa and India.^[1,2] *Nocardia* species though it can infect immunocompetent individuals, it most commonly infects immunocompromised patients. Patients at risk of acquiring this infection includes persons with underlying disease like malignancy (3–4%), pulmonary disease (12%) or immunodepression (17–30%). A significant number of infected persons, however, appear to have no pre-disposing factors (15-71%). The most frequent primary site of involvement

is the pulmonary system (73%). Diseases can disseminate to almost any organ system. Secondary sites are brain (45%) meninges, spinal cord (23%), skin and subcutaneous tissue (9%), pleura and chest wall (8%).^[3] Mortality is highest in patients with disseminated disease.^[4,5]

Nocardiosis is commonly mistaken for pneumonia, tuberculosis, histoplasmosis, actinomycetes, lung cancer or bacterial abscess. In immunocompetent patients Nocardiosis usually presents as cutaneous or subcutaneous lesions and is generally caused by *N. asteroides*. The incidence of primary Nocardiosis reported in English literature was 5% (Palmer *et al.*)^[3,6] although data regarding overall incidence of primary Nocardiosis was not available in India as only few cases have been documented.

Nocardia causes primary disease in the skin by its traumatic introduction from soil. This primary skin infection is rare, often with a sub-acute course, presenting as cellulitis, lymphocutaneous disease or mycetoma in the immunocompetent patient.^[7] Mycetoma is a chronic, localized infection of the dermis and sub-cutaneous tissue with indolent swelling and draining sinuses. Walking barefoot and working outdoors in rural settings are particularly at risk.^[8]

Three factors are thought to be important for the development of mycetoma: the inoculum, the patient's immune status and hormonal adaptation.^[2] Progression to fibrosis, mutilation and finally loss of function is rapid in actinomycotic nocardial mycetoma cases. Bone involvement is rare and occurs infrequently.^[8]

Patients with primary sub-cutaneous Nocardiosis respond well to medical treatment. Cotrimoxazole is the main stay of

treatment and other effective drugs are Dapsone, Amikacin and Ciprofloxacin. In our patient, a good response was observed with combination therapy.^[6] Despite characteristic clinical feature, our patient remained undiagnosed for long, may be because it is difficult to diagnose clinically. Hence subcutaneous nocardiosis should be kept as one of the differential diagnosis. To overcome the problem of delayed or no diagnosis, clinical correlation along with good biopsy and repeated microscopy need to be emphasized.^[8]

A high index of clinical suspicion is needed for the diagnosis of the condition along with the stringent efforts of microbiologists to isolate the organism.

REFERENCES

1. Bonifaz A, Ibarra G, Saúl A, Paredes-Solis V, Carrasco-Gerard E, Fierro-Arias L. Mycetoma in children: Experience with 15 cases. *Pediatr Infect Dis J* 2007;26:50-2.
2. Lovell P. Mycetoma: In: Canizava O, Harman RR, editors. *Clinical tropical dermatology*. 2nd ed. Boston; Blackwell Scientific Publications; 1992. p. 41-90.
3. Palmer DL, Harvey RL, Wheeler JK. Diagnostic and therapeutic considerations in *Nocardia asteroides* infection. *Medicine* 1974;53:391-401.
4. David B, Yanoff MD, McGregor L, Church MD. Nocardial vertebral osteomyelitis. USA: *Clinical orthopedics and related researches*; 1983. p. 223-6.
5. Curry WA. Human Nocardiosis. A clinical review with selected case reports. *Arch Intern Med* 1980;140:818-26.
6. Barodkar VP, Mathur M, Kulkarni SD, Kumar S. Sporotrichoid pattern of cutaneous nocardiasis due to *Nocardia asteroides*. *Indian J Pathol Microbiol* 2008;51:432-4.
7. Chedid MB, Chedid MF, Porto NS, Severo CB, Severo LC. Nocardial infections: Report of 22 cases. *Rev Inst Med Trop Sao Paulo* 2007;49:239-46.
8. Sharma NL, Mahajan VK, Agarwal S, Katoch VM, Das R, Kashyap M, *et al.* Nocardial mycetoma: Diverse clinical presentation. *Indian J Dermatol Venereol Leprol* 2008;74:635-40.

How to cite this article: Hogade S, Metgud SC, S. Actinomycetes mycetoma. *J Lab Physicians* 2011;3:43-5.

Source of Support: Nil. **Conflict of Interest:** None declared.

Staying in touch with the journal

1) Table of Contents (TOC) email alert

Receive an email alert containing the TOC when a new complete issue of the journal is made available online. To register for TOC alerts go to www.jlponline.org/signup.asp.

2) RSS feeds

Really Simple Syndication (RSS) helps you to get alerts on new publication right on your desktop without going to the journal's website. You need a software (e.g. RSSReader, Feed Demon, FeedReader, My Yahoo!, NewsGator and NewzCrawler) to get advantage of this tool. RSS feeds can also be read through FireFox or Microsoft Outlook 2007. Once any of these small (and mostly free) software is installed, add www.jlponline.org/rssfeed.asp as one of the feeds.