

Case Report

Metastasis of maxillary sinus adenoid cystic carcinoma to the humerus bone—A rare case report

Mala Sagar¹, Anurag Singh¹, Sumairya Qayoom¹, U. S. Singh¹

¹Department of Pathology, King George Medical University, Lucknow, Uttar Pradesh, India.

*Corresponding author:

Anurag Singh, MD,
Department of Pathology, King
George Medical University,
Lucknow 226003, Uttar
Pradesh, India

anugsvm@yahoo.com

Received: 29 December 2022
Accepted: 01 March 2023
Epub Ahead of Print: 28 August 2023
Published: 08 June 2024

DOI

10.1055/s-0043-1772851

Quick Response Code:



This article was published by
Thieme Medical and Scientific
Publishers Pvt. Ltd. as online first

ABSTRACT

Adenoid cystic carcinoma accounts for 10 to 12% of all salivary gland malignant neoplasms with an estimated incidence of 3 to 4.5 cases per million per year. Perineural spread and multiple local recurrences are its defining features, although the liver and lung are the most frequent sites for distant metastases. It is extremely uncommon for adenoid cystic carcinoma of the maxillary sinus to spread to distant bones. Few cases of adenoid cystic carcinoma with distant bone metastasis have been reported. Here, we report a known case of the adenoid cystic carcinoma of the maxillary sinus in a 40-year-old male, with isolated metastasis to the left humerus bone presenting 4 years later to the excision of the primary lesion. The fine-needle aspiration cytology, trucut biopsy, and immunocytochemistry of the left humerus osteoexpansile lesion confirmed the diagnosis of metastatic adenoid cystic carcinoma. This rare case report re-emphasizes the distant metastatic potential of adenoid cystic carcinoma.

Keywords: Adenoid cystic carcinoma, humerus bone, maxillary sinus, metastasis

INTRODUCTION

Adenoid cystic carcinoma (ACC) accounts for 10 to 12% of all salivary gland malignant neoplasms with an estimated incidence of 3 to 4.5 cases per million per year.^[1] Perineural spread and repeated local recurrences are the primary characteristics of ACC, while lung and liver are the most prevalent distant sites of metastases.^[2] Remote bone metastases from ACC of the salivary gland are relatively uncommon.^[3] Few reports of ACC with bone metastases have been recorded so far.^[4,5] Here, we describe a case of a 40-year-old man who underwent excision of primary ACC of the left maxillary sinus and developed left humerus bone metastases 4 years later. The possibility for distant metastasis of ACC is re-emphasized by this unusual case report.

CASE REPORT

A 40-year-old man presented to the department of oncosurgery with chief complaints of left cheek swelling associated with severe pain, and reduced sensation over the left side of the face. He also complained of on and off fever and generalized weakness. There was no history of trauma or previous surgery. The plain and contrast-enhanced computed tomography (CT) scan of paranasal sinuses (PNS) and head showed a hypervascular, infiltrative mass measuring 5.5 × 3.8 × 3.2 cm, epicenter at maxillary sinus, and eroding the anterior wall of the maxilla, posterior maxillary

This is an open-access article distributed under the terms of the Creative Commons Attribution-Non Commercial-Share Alike 4.0 License, which allows others to remix, transform, and build upon the work non-commercially, as long as the author is credited and the new creations are licensed under the identical terms.

©2024 Published by Indian Association of Laboratory Physicians

sinus, posterolateral part of the hard palate, orbital floor, and adhered to periorbital tissue. No intraconal extension was noted.

Left total maxillectomy via mid-face degloving approach under general anesthesia was done with osteotomies over the maxilla along with medial, anterior, and posterior wall removal. On gross examination of resected specimen, infiltrative rubbery tan white mass was identified, measuring $4.5 \times 3.0 \times 2.5$ cm extending close to the resected margins. The histopathology of the resected specimen was ordered that showed tumor disposed of in cribriform pattern and tubules filled with eosinophilic hyaline material. The tumor cells displayed round to oval hyperchromatic angulated nuclei, inconspicuous nucleoli, and scant amount of cytoplasm (Figure 1A, B). All the resection margins of the maxillectomy specimen were free from tumor invasion. Based on histomorphology, diagnosis of ACC was rendered. The postoperative plain CT of PNS was performed that showed no evidence of any enhancing lesion (Figure 1C).

The patient underwent a free flap repair and four stereotactic radiation sessions along with four cycles of platinum-based

chemotherapy. After 4 years of initial diagnosis, he noticed a painful lump in his lower part of left arm (Figure 2A). The X-ray of the left arm was performed that showed an ill-defined enhancing osteoexpansile soft tissue lesion involving the distal shaft of left humerus (Figure 2B). Subsequently, fluorodeoxyglucose positron emission tomography-computed tomography whole body imaging displayed metabolically active bone and marrow lesions involving the distal part of left humerus with the cortical breach. No other metabolically active residual/recurrent disease is noted elsewhere in the body (Figure 2C).

The ultrasound-guided fine-needle aspiration cytology (FNAC) and trucut biopsy were performed from the left arm lump. The FNAC smears from left-hand swelling were cellular and showed papillary fragments of mild anisomorphic basaloid-type malignant epithelial cells on an eosinophilic hyaline background. These tumor cells displayed round to oval hyperchromatic nuclei, indistinct nucleoli, and scant cytoplasm (Figure 3A, B).

The section from trucut biopsy from the left arm lump also showed similar morphology of tumor cells as the

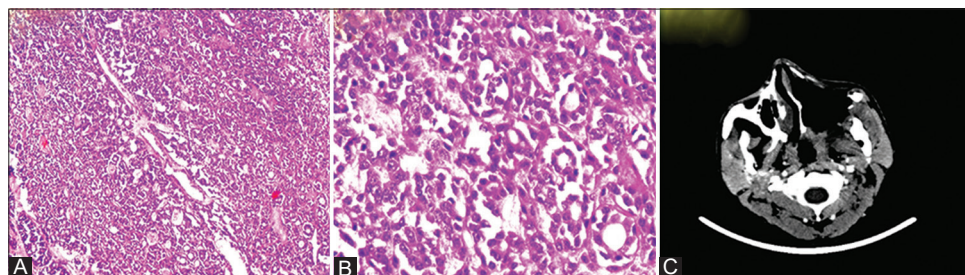


Figure 1: (A) Maxillary sinus tumor (hematoxylin and eosin [H&E] stain 40X). (B) Maxillary sinus tumor (H&E stain 400X). (C) Postoperative plain computed tomography of paranasal sinus.

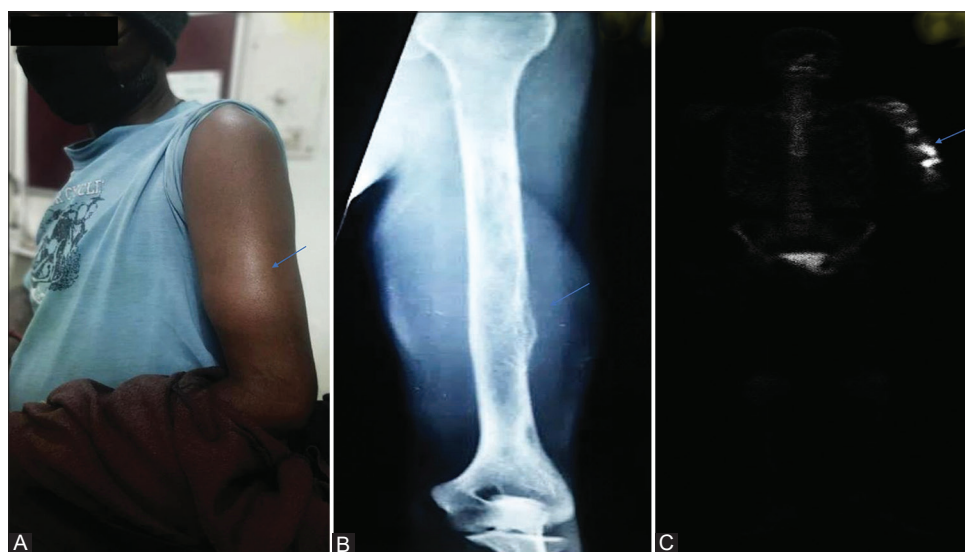

Figure 2: (A) Clinical photograph of the patient. (B) X-ray of the left arm. (C) Fluorodeoxyglucose positron emission tomography-computed tomography whole body imaging.

Table 1: List of cases of adenoid cystic carcinoma with distant bone metastasis

Sl. no.	Age/sex	Site of primary lesion	Site of distant metastasis	Duration between excision of primary lesion and distant metastasis	Treatment	Author, year
1.	62/F	Submandibular gland	Left big toe bone	8 years	Surgery with radiotherapy	Zhang et al. 2019 ^[4]
2.	52/M	Submandibular gland	Right toe	12 years	Radiotherapy	Rafael et al. 2016 ^[2]
3.	37/M	Left maxillary sinus	Lower spinal column and acetabulum	Presented with metastasis	Palliative radiation therapy along with adjunctive doxorubicin chemotherapy	Lee et al. 2004 ^[13]
4.	62/M	Submandibular gland	Intraspinal metastasis (L3-L4)	15 years	Decompression with palliative radiotherapy	Birkeland., 2003 ^[14]
5.	52/M	Submaxillary gland	Left great toe	8 months	NA	Weitzner 1975 ^[5]
Index case	40/M	Maxillary sinus	Left humerus bone	4 years	Died before start of treatment	–

Abbreviation: NA, not available.

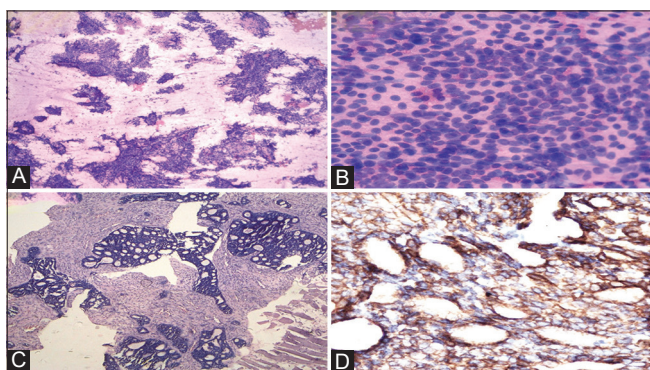


Figure 3: (A) Fine-needle aspiration cytology (FNAC) from left-arm swelling (May Grunwald-Giemsa stain 100X). (B) FNAC from left-arm swelling (MGG stain 400X). (C) Trucut biopsy left arm (hematoxylin and eosin stain 40X). (D) Immunohistochemistry: anti-c-kit antibody (40X).

primary lesion of the maxillary sinus (Figure 3C). Immunohistochemistry was also applied on trucut biopsy that displayed diffuse cytoplasmic expression for anti-c-kit antibody in the tumor cells (Figure 3D). A definitive diagnosis of metastatic ACC to the left humerus (follow-up case of maxillary sinus ACC) was rendered. The patient had been planned for further management, but unfortunately, he succumbed to his illness after 3 months of detection of metastasis.

DISCUSSION

ACC of salivary gland is a relatively uncommon neoplasm. Only 3 to 5% of head and neck and 5 to 15% of sinonasal malignant neoplasms are ACC.^[6] The patients' age range for ACC is from 28 to 84 years with a median of 54.^[5] years.^[7] It can develop in various other organs, including the esophagus,

uterine cervix, breast, lung, prostate, and tracheobronchial tree.^[8] They spread most frequently to the liver and lungs. However, only 1.96% of metastases involve the bones, and metastases through the hematogenous route to distant bones are relatively rare.^[9,10] Following bony metastases, there is a brief period of survival, often lasting 10 months.^[11] Our patient died after 3 months of detection of bone metastases. Only a small number of cases of ACC with distant bone metastasis have been documented in the literature (Table 1).

A careful analysis of pertinent literature revealed that distant metastases to bone are incredibly uncommon. ACC spreads relentlessly to local and distant structures through direct extension or hematolymphatic pathway.^[11] The majority of patients die 5 to 10 years after initial treatment, and it has a significant mortality rate. After 4 years of initial treatment, our patient also passed away with isolated bone metastasis.

There are no established treatment guidelines for cases of distant bone metastases in the postoperative cases of maxillary sinus ACC. Whenever there are superior alternatives to surgical resection, such as stereotactic radiation and platinum-based chemotherapy, they should be considered. In metastatic cases of ACC, targeted therapy such as anti-fibroblast growth factor, epidermal growth factor receptor, and tyrosine kinase inhibitors must be assessed because, as of yet, there is no long-term evidence to support their efficacy.^[12]

CONCLUSIONS

ACC of the maxillary sinus with distant bone metastases is a very uncommon condition that requires case-specific treatment. Due to the few chemotherapeutic regimens available and the tendency for late metastases at distant sites, the prognosis for ACC with metastatic disease is extremely

poor. This rare case report re-emphasizes the distant metastatic potential of ACC and hence such patients should be kept under regular follow-up for long periods.

Financial Support and Sponsorship

None.

Ethical Clearance

Approved.

Conflicts of Interest

None declared.

REFERENCES

- De Berardinis R, Viziano A, Micarelli A, et al. Adenoid cystic carcinoma of head and neck. *Am J Otolaryngol Head Neck Surg* 2018;1:1010.
- Rafael OC, Paul D, Chen S, Kraus D. Adenoid cystic carcinoma of submandibular gland metastatic to great toes: case report and literature review. *Clin Case Rep* 2016;4:820–823.
- Mücke T, Tannapfel A, Kesting MR, et al. Adenoid cystic carcinomas of minor salivary glands. *Auris Nasus Larynx* 2010;37: 615–620.
- Zhang J, Sun Y, Li Z, Feng H. Metastasis of submandibular gland carcinoma to the toe bone: a case report. *Br J Oral Maxillofac Surg* 2019;57:368–370.
- Weitzner S. Adenoid cystic carcinoma of submaxillary gland metastatic to great toe. *Am Surg* 1975;41:655–658.
- Cantù G Adenoid cystic carcinoma. An indolent but aggressive tumour. Part A: from aetiopathogenesis to diagnosis. *Acta Otorhinolaryngol Ital* 2021;41:206–214.
- Bianchi B, Copelli C, Cocchi R, Ferrari S, Pederneschi N, Sesenna E. Adenoid cystic carcinoma of intraoral minor salivary glands. *Oral Oncol* 2008;44:1026–1031.
- Coca-Pelaz A, Rodrigo JP, Bradley PJ, et al. Adenoid cystic carcinoma of the head and neck—An update. *Oral Oncol* 2015;51: 652–661.
- Balducci G, Sagnotta A, Muroli M, Cacchi C, D'Amato A. An unusual case of exclusive liver metastases from adenoid cystic carcinoma of the submandibular gland: a role for surgery? Report of a case. *Surg Today* 2011;41:596–599.
- van der Wal JE, Becking AG, Snow GB, van der Waal I. Distant metastases of adenoid cystic carcinoma of the salivary glands and the value of diagnostic examinations during follow-up. *Head Neck* 2002;24:779–783.
- Harish K, Gouri SRM Adenoid cystic carcinoma of the parotid metastasizing to liver: case report. Accessed August 16, 2023 at: <http://bmccancer.biomedcentral.com/articles/10.1186/1471-2407-4-41>.
- Yaga US, Gollamudi N, Mengji AK, et al. Adenoid cystic carcinoma of the palate: case report and review of literature. *Pan Afr Med J* 2016;24:106.
- Lee WJ, Kapadia SB, Stack BC Jr. Sinonasal adenoid cystic carcinoma with widespread symptomatic bony metastasis. *Ear Nose Throat J* 2004;83:271–273.
- Birkeland S. Spinal metastasis of submandibular gland adenoid cystic carcinoma: a case report. *Surg Neurol* 2003;60: 265–266.

How to cite this article: Sagar M, Singh A, Qayoom S, Singh US. Metastasis of maxillary sinus adenoid cystic carcinoma to the humerus bone—A rare case report. *J Lab Physicians*. 2024;16:219-22. doi: 10.1055/s-0043-1772851