

Hepatitis-B Associated Cryoglobulinemia Presenting as Pseudoleukocytosis

Sir,

Cryoglobulins are serum immunoglobulin (Ig) or immunoglobulin complexes that undergo reversible precipitation at low temperatures.^[1] Cryoglobulins may interfere with automated cell counting when immunoglobulins precipitate.^[2] This results in spuriously high leukocyte counts, platelet count and false values for red blood cell parameters.^[2] Pseudoleukocytosis may be the first indication of the presence of a cryoglobulinemia

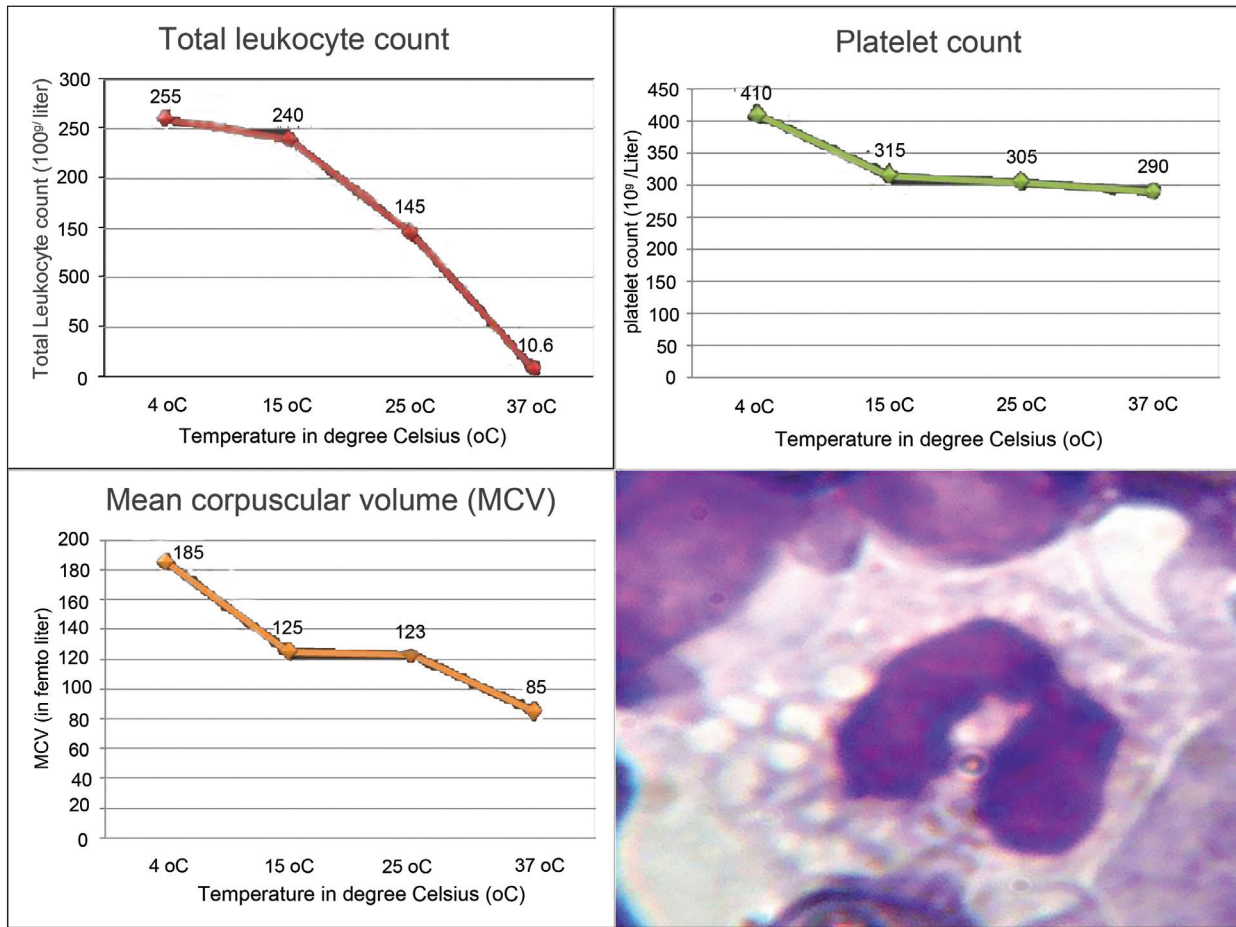


Figure 1: Effect of warming of blood on total leukocyte count, mean corpuscular volume, and platelet count from automated cell counter (Sysmex kx 21). Also showing the peripheral blood smear revealing inclusion bodies in neutrophils (Giemsa stain x1000)

and this should indicate both clinician and pathologist to search for the underlying cause.^[1,3] The spurious leukocytosis was previously described in several case reports, but values as high as 255,000 cells/microliter were never reported.

We describe a case of 12-year-old boy who presented in the month of January with jaundice, seizures, and vomiting and was delirious on examination. He was diagnosed to be a case of acute hepatic failure with stage IV hepatic encephalopathy. The liver function test was deranged. On further analysis hepatitis-B surface antigen was found to be positive. Complement levels were extremely low. Automated total leukocyte count (TLC) was found to be 255,000 cells/microliter. On peripheral smear TLC appears to be in the normal range. On manual counting, by Neubauer's chamber, TLC was 10,600 cells/microliter. The careful examination of peripheral blood smear revealed inclusion body in neutrophils [Figure 1].

The complete blood count was repeated on the prewarmed blood specimen at 15°C, 25°C, and 37°C on automatic analyzer (Sysmex kx 21). The change in the values of

total leukocyte count, platelet count along with red cell parameters like mean corpuscular volume, strengthened the suspicion of the presence of cryoprotein interference [Figure 1]. Use of citrate-anticoagulated blood gives the same results as prewarmed blood at 37°C.

Final diagnosis was made on biochemical analysis of the serum; its isolation, purification, and immunochemical analysis. IgG fraction was polyclonal along with monoclonal IgM (type II). The final diagnosis was made as hepatitis-B with type II cryoglobulinemia with stage IV hepatic encephalopathy.

In 1974, Brouet *et al.*^[1] classified cryoglobulinemia into three types (I, II, and III). Types II and III are associated with hepatitis B virus infection. Other causes of cryoglobulinemia include various infectious, renal disorders, autoimmune disorders, hematological (especially multiple myeloma and lymphoproliferative disorders), and neoplastic diseases.^[4] Cryoglobulinemia may be diagnosed several years before the underlying cause, especially for hematological diseases.^[1,3] They can also occur in the absence of any apparent relevant disease.^[4] Cryoglobulins,

on precipitation, form particles of various sizes ranging from 3µm to 24 µm. This size range interferes with blood cell counts ascertained by automated cell counters (Sysmex kx 21). It has been demonstrated that cryoglobulin containing plasma might induce the generation of neutrophil inclusions in neutrophils from a healthy donor.^[5] Ultrastructural and immunofluorescence studies have shown that the cytoplasmic inclusions in neutrophils corresponded to the cryoglobulin, likely phagocytosed by these cells.^[5]

Recognition of the cryoglobulin is important to correct factitious results with automated blood cell counters. Leukocytosis and thrombocytosis unsubstantiated by examination of a peripheral blood film and manual count should raise the suspicion of cryoglobulinemia. Cryoglobulin-induced laboratory artifacts and pseudoleukocytosis on automated counters may be the first factors prompting the assessment for cryoglobulinemia and the diagnosis of the underlying cause.

**Yogesh Kr. Yadav, Roopak Aggarwal,
Oneal Gupta, Sunil Ranga**

Department of Pathology, Safdarjung Hospital and
Vardhman Mahavir Medical College, New Delhi, India

Address for correspondence: Dr. Yogesh Kumar Yadav,
E-mail: dr.yogi007@gmail.com

REFERENCES

1. Brouet JC, Clauvel JP, Danon F, Klein M, Seligmann M. Biologic and clinical significance of cryoglobulins: A report of 86 cases. *Am J Med* 1974;57:775-88.
2. Keshgegian AA, Van Tran N. (Lankenau Hospital case conference) Mixed cryoglobulinemia causing pseudoleukocytosis. *Clin Chem* 1985;31:769-73.
3. Lesesve JF, Goasguen J. Cryoglobulin detection from a blood smear leading to the diagnosis of multiple myeloma. *Eur J Haematol* 2000;65:77.
4. Barnett EV, Bluestone R, Cracchiolo A, Goldberg LS, Kantor GL, McIntosh RM. Cryoglobulinemia and disease. *Ann Intern Med* 1971;73: 95-107.
5. Maitra A, Ward PC, Kroft SH, Levinson BS, Jamal S, Fishleder AJ, *et al.* Cytoplasmic inclusions in leukocytes: An unusual manifestation of cryoglobulinemia. *Am J Clin Pathol* 2000;113:107-12.

Access this article online

Quick Response Code:



Website:
www.jlponline.org

DOI:
10.4103/0974-2727.86854