

Multifocal Keloids Associated with *Mycobacterium fortuitum* following Intralesional Steroid Therapy

Shailesh Kumar, Noyal Mariya Joseph, Joshy M Easow, Sivaraman Umadevi

Department of Microbiology, Mahatma Gandhi Medical College and Research Institute, Pondicherry, India

Address for correspondence: Dr. Shailesh Kumar, E-mail: shaileshgar@yahoo.com

ABSTRACT

We report a case of subcutaneous abscess formation with *Mycobacterium fortuitum* following intralesional steroid injection into multifocal keloids. A high index of suspicion of atypical mycobacteria infection is needed in patients with a history of skin and soft tissue infections, in particular late-onset infections, which are negative for routine bacterial cultures and without a clinical response to antibiotics used for acute pyogenic infections.

Keywords: Abscess, keloid, *Mycobacterium fortuitum*

INTRODUCTION

The occurrence of cutaneous nontuberculous mycobacterial (NTM) infections is being increasingly reported. Although most pathogenic species of NTM may cause skin and soft tissue infections, *Mycobacterium marinum*, *Mycobacterium ulcerans* and the rapidly growing mycobacteria such as *Mycobacterium fortuitum*, *Mycobacterium chelonae* and *Mycobacterium abscessus* are the most frequent causes.^[1] Cutaneous infections by NTM usually occur following contact of surgical or traumatic wounds with water or other contaminated source. In addition, among the immunosuppressed it can occur as a consequence of a disseminated mycobacterial disease. A high index of suspicion about NTM infections is necessary, in those with chronic infections of the skin and soft tissue, to ensure prompt and appropriate treatment.^[1] Abscess formation at the site of the puncture wound is most often due to rapidly growing mycobacteria. Wallace and coworkers noted that *M. fortuitum* and *M. chelonae* were the predominant isolates when they reviewed 125 cases of human infections caused by

rapidly growing mycobacteria. Among these 59% had cutaneous infections following surgery, accidental trauma or needle injections.^[2] We report a case of subcutaneous abscesses due to *M. fortuitum* following intralesional steroid in a patient with multifocal keloids. Literature from our subcontinent suggests association of mycobacterial infection following yellow jacket sting and recurrent soft tissue infections.^[3,4] However, we were unable to retrieve literature regarding association of keloids with *M. fortuitum* following a PubMed search, which emphasizes the uniqueness of our report.

CASE REPORT

A 61-year-old man who is a known diabetic and hypertensive, presented with multiple keloid lesions of 5-years duration. He noticed that the size increased gradually over a period of time which prompted him to consult a dermatologist, who administered intralesional steroid injection. The patient noticed progressive increase in size of the larger lesion followed by formation of sinuses and drainage of pus. A diagnosis of pyogenic abscess was made and he was advised local application of cephalexin and cotrimoxazole; as there was no response, he was referred to our hospital.

On examination he was afebrile and there were no palpable lymph nodes. Multiple keloids were observed

Access this article online	
Quick Response Code: 	Website: www.jlponline.org
	DOI: 10.4103/0974-2727.86850

over the manubrium, the intermammary region (largest lesion measuring 8 × 3 × 2 cm) [Figure 1] and above the right nipple. The lesion in the intermammary region was associated with sinuses which was discharging pus. He had no family history of keloids. No abnormal findings were seen in his blood picture and chest X-ray. Sputum for acid-fast bacilli (AFB) and Mantoux test were negative. Serology for HIV and VDRL were non-reactive.

Pus was aspirated from the lesions for microbiological studies. Gram stain showed plenty of pus cells but no bacteria, while Ziehl-Neelsen stain revealed a few short, acid-fast bacilli in a background of polymorphs raising the possibility of mycobacteria [Figure 2]. Routine bacterial culture of the pus was reported as sterile. However, culture on Lowenstein-Jensen media (LJ) grew organism suspected to belong to *M. fortuitum* - *chelonae* complex based on the rapid growth and positivity for biochemical tests such as catalase, urease and arylsulfatase. It was phenotypically identified as *M. fortuitum*, as the isolate grew on MacConkey agar (without crystal violet), reduced nitrate and was susceptible to ciprofloxacin. Histopathology confirmed the diagnosis of keloid based on the presence of thick, hypereosinophilic bands of collagen; the underlying lesion showed granuloma composed of epithelioid histiocytes and giant cells, usually of Langhans' type. The patient showed a good response after 6 months of treatment with amikacin and clarithromycin.

DISCUSSION

Keloids appear spontaneously or following trauma, may expand beyond the margin of the wound, and persists for years as in encountered in our case. NTM are known to produce subcutaneous lesion following minor trauma, the commonest etiological agent being *M. marinum* acquired following a swim in infected pools or immersion in aquaria.^[5-7] Rapidly growing mycobacteria are a complex group of environmental mycobacteria which is either pigmented or non-pigmented. They are found ubiquitously in the environment including water, soil, dust, wild and domestic animals and fish.^[8] They can grow in municipal water systems and distilled water. They are resistant to sterilizers, antiseptics, standard disinfectants including 10% povidine-iodine, 2% aqueous formaldehyde and 2% alkaline glutaraldehyde.^[9] These mycobacteria are known to cause cutaneous infections, typically in association with trauma or clinical procedures as in our case. Their optimal incubation temperature ranges from 25°C to 40°C, and are characterized by a rapid growth rate (within 7 days) on subculture. *M. fortuitum* is one of several

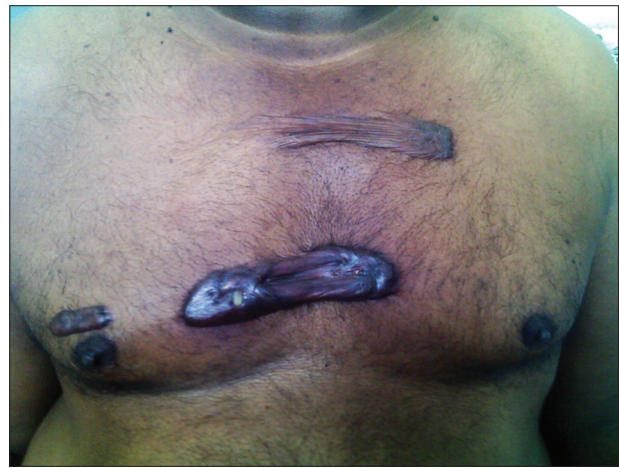

Figure 1: Clinical photograph of multiple keloid lesions on the chest

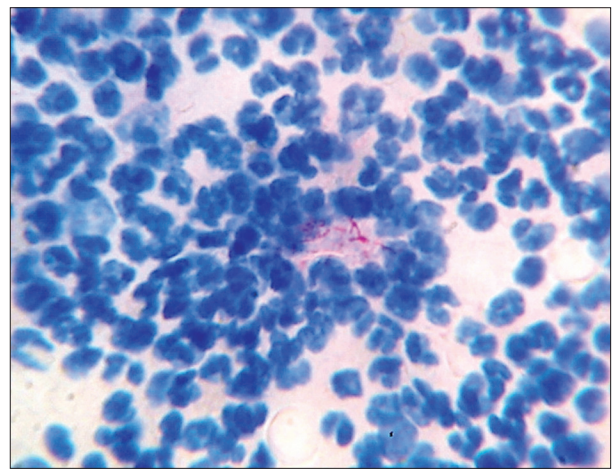


Figure 2: Acid-fast bacilli seen on Ziehl-Neelsen staining of the aspirate from the lesion

rapidly growing mycobacteria, which is increasingly being recognized to cause human disease.^[8] Uslam *et al.* reported that patients with *M. fortuitum* skin and soft infections were younger unlike in our case and were less likely to be immunocompromised when infected with *M. chelonae*.^[10] As observed in our patient, the clinical manifestations consist of draining sinuses and abscesses, ulcers and nodules that can evolve into scaly plaques or can even mimic cellulitis; however, fever, chills and systemic manifestation are infrequent.^[8,9] Delayed diagnosis of cutaneous infections due to *M. fortuitum* is a common clinical issue. Causes of delayed diagnosis are multiple and include resemblance to pyogenic infections, lack of awareness and a low index of suspicion among physicians. In general, the organism is usually susceptible *in vitro* to amikacin, cefoxitin, imipenem, sulfonamides and flouroquinolones.^[11,12] Combination therapy seems prudent initially because of concerns about resistance.^[10,13] It should include two or three antibiotics to which the organism is susceptible. Treatment should be continued for 3 months or until the resolution of

clinical manifestations. In our case, the patient responded well to treatment with a combination of amikacin and clarithromycin for a period of 6 months.

In conclusion, physicians should think outside the box when faced with chronic skin lesions, as the consequence of failing to make an early diagnosis may lead to necrosis, destruction of underlying bones and cartilage. With increasing clinical use of intralesional steroids, treating physicians will probably identify more of these cases based on the awareness that this report presumably will create.

REFERENCES

1. Chen HY, Chen CY, Huang CT, Ruan SY, Chou CH, Lai CC, *et al.* Skin and soft-tissue infection caused by non-tuberculous mycobacteria in Taiwan, 1997-2008. *Epidemiol Infect* 2011;139:121-9.
2. Wallace RJ Jr, Swenson JM, Silcox VA, Good RC, Tschen JA, Stone MS. Spectrum of disease due to rapidly growing mycobacteria. *Rev Infect Dis* 1983;5:657-79.
3. Singh S, Rattan A, Kumar S. Severe cutaneous *Mycobacterium chelonae* infection following a yellow jacket sting. *Tuber Lung Dis* 1992;73:305-6.
4. Sarma S, Thakur R. Cutaneous infection with *Mycobacterium fortuitum*: An unusual presentation. *Indian J Med Microbiol* 2008;26:388-90.
5. Okano A, Shimazaki C, Ochiai N, Hatsuse M, Takahashi R, Ashihara E, *et al.* Subcutaneous infection with *Mycobacterium fortuitum* after allogeneic bone marrow transplantation. *Bone Marrow Transplant* 2001;28:709-11.
6. Kuo Y, Chiou H, Chou Y, Chiou S, Chang C. Solitary subcutaneous non-tuberculous mycobacterial infection: A case report and its ultrasound appearance. *Chin J Radiol* 2004;29:47-51.
7. Subbarao EK, Tarpay MM, Marks MI. Soft-tissue infections caused by *Mycobacterium fortuitum* complex following penetrating injury. *Am J Dis Child* 1987;141:1018-20.
8. Sehgal VN, Bhattacharya SN, Jain S, Logani K. Cutaneous tuberculosis: The evolving scenario. *Int J Dermatol* 1994;33:97-104.
9. Chin PW, Koh CK, Wong KT. Cutaneous tuberculosis mimicking cellulitis in an immunosuppressed patient. *Singapore Med J* 1999;40:44-5.
10. Uslan DZ, Kowalski TJ, Wengenack NL, Virk A, Wilson JW. Skin and soft tissue infections due to rapidly growing mycobacteria: Comparison of clinical features, treatment, and susceptibility. *Arch Dermatol* 2006;142:1287-92.
11. Murillo J, Torres J, Bofill L, Rios-Fabra A, Irausquin E, Isturiz R, *et al.* Skin and wound infection by rapidly growing mycobacteria: An unexpected complication of liposuction and liposculpture. The Venezuelan Collaborative Infectious and Tropical Diseases Study Group. *Arch Dermatol* 2000;136:1347-52.
12. Behroozan DS, Christian MM, Moy RL. *Mycobacterium fortuitum* infection following neck liposuction: A case report. *Dermatol Surg* 2000;26:588-90.
13. Wallace RJ Jr. The clinical presentation, diagnosis, and therapy of cutaneous and pulmonary infections due to the rapidly growing mycobacteria, *M. fortuitum* and *M. chelonae*. *Clin Chest Med* 1989;10:419-29.

How to cite this article: Kumar S, Joseph NM, Easow JM, Umadevi S. Multifocal keloids associated with *Mycobacterium fortuitum* following intralesional steroid therapy. *J Lab Physicians* 2011;3:127-9.

Source of Support: Nil. **Conflict of Interest:** None declared.