

Cold Agglutinin Disease with Erythrophagocytosis by Neutrophils Occurring During Recovery Phase of Chickenpox

Sir,

A 16-years-old girl recovering from chickenpox presented with acute onset pallor and jaundice. On examination, she was very pale and icteric and had scabs all over her body. There was no fever or organomegaly. Her vitals were stable. However, a complete blood count revealed markedly low hemoglobin of 2.8 gm/dL, with normal total leucocyte count and platelets. Her peripheral blood film revealed red blood cell (RBC) agglutinates, with mainly normochromic normocytic RBCs along with marked polychromasia and few nucleated RBCs. Schistocytes were not seen. Neutrophils showed toxic granules, vacuolations, and erythrophagocytosis by 10% neutrophils [Figure 1]. Reticulocyte count was 12%. Serum total bilirubin was 11.3 mg/dL, most of which was indirect bilirubin 11.1 mg/dL. Her serum potassium was 5.2 mmol/L and LDH was 1620 U/L.

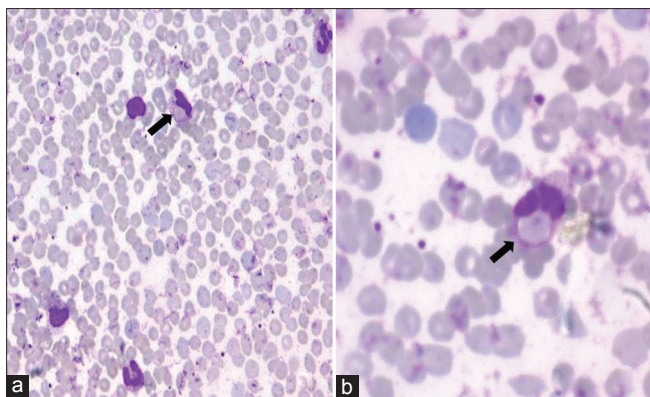


Figure 1: (a, b) Post-transfusion peripheral blood film prepared after incubation of blood at 37°C showed erythrocytes in small clumps and rouleaux formation. Polychromatophils and occasional erythrophagocytosis by neutrophils (solid black arrow) can be seen

Further tests performed showed positive direct coombs test and cold agglutinin titers of 1:512. Her Donath-Landsteiner antibody test and ANA panel were negative.

During her stay in the hospital, she was treated symptomatically and was transfused with packed RBCs. She showed good recovery and was discharged after a week of hospital stay.

Cold agglutinin disease occurring during recovery phase of chickenpox is a very rare phenomenon. IgM binds to red cells at low temperatures in the peripheral parts of the body and activates the complement. Lysis mainly occurs when these RBCs enter the central circulation. The C3b attached on the RBC surface makes them vulnerable to rapid removal by splenic and hepatic phagocytes, which is why cold agglutinin disease is not associated with peripheral blood schistocytes.^[1] To the best of our knowledge, only nine cases of AIHA after chickenpox are available in the literature, including the warm AIHA, cold AIHA, paroxysmal cold hemoglobinuria, and mixed-type AIHA.^[2-5] Cold agglutinin disease with erythrophagocytosis by neutrophils in recovery phase of chickenpox is very rarely reported. We hope that

this case would help increase awareness of this rare and treatable complication of chickenpox among all directly or indirectly involved in patient care.

ACKNOWLEDGMENTS

The authors would like to thank late Dr. B.C. Sangal, Chief Pathologist of our Department, who always inspired us to publish good research work done in the department and Dr. Shilpi Bhargava for her assistance in literature search.

**Harpreet Walia, Rohit Jain,
Rajiv Kumar Bansal¹, Gajendra Nath Gupta**

Departments of Pathology and Transfusion Medicine and
¹Pediatrics, Santokba Durlabhji Memorial Hospital, Jaipur,
Rajasthan, India

Address for correspondence: Dr. Rohit Jain,
E-mail: funkyaarjay@yahoo.com

REFERENCES

1. Smith LA. Hemolytic anemia: Immune anemias. In: McKenzie SB, editor. *Clinical Laboratory Hematology* 2nd ed. New Jersey: Pearson Education; 2004. p. 355-7.
2. Friedman HD, Dracker RA. Intravascular erythrophagocytosis. *JAMA* 1991;265:1082.
3. Johnson AM. Cold agglutinin disease after chickenpox. *Am J Clin Pathol* 1992;98:271-2.
4. Tanaka Y, Masuya M, Katayama N, Miyata E, Sugimoto Y, Shibasaki T, *et al.* Development of mixed-type autoimmune hemolytic anemia and Evans' syndrome following chicken pox infection in a case of low-titer cold agglutinin disease. *Int J Hematol* 2006;84:220-3.
5. Chandrashekar V, Soni M. Florid erythrophagocytosis on the peripheral smear. *J Lab Physicians* 2012;4:59-61.

Access this article online	
Quick Response Code: 	Website: www.jlponline.org
	DOI: 10.4103/0974-2727.119873