

Renal Type Clear Cell Carcinoma of the Prostate: A Diagnostic Dilemma

Sir,

Clear cell lesions of the urinary tract including the prostate often present a diagnostic challenge.^[1] Clear cell carcinomas that may occur in the prostate include variants of prostate adenocarcinoma, transitional cell carcinoma, and metastatic renal cell carcinoma (RCC). However, metastasis to the prostate from the RCC is very rare. Renal type clear cell adenocarcinoma occurring as primary tumor in an extra renal location, especially in the prostate is very rare and was described in 2003.^[2,3] We report an unusual case of renal type clear cell carcinoma of prostate histologically mimicking metastatic clear cell RCC.

A 64-year-old male presented with poor stream, dribbling of urine with overflow incontinence since 2 months. Per rectal examination revealed Grade II enlarged, firm to hard prostate. Urine culture revealed no growth. Ultrasound abdomen revealed grade II enlarged prostate with thickened bladder wall and mild hydroureteronephrosis on the left side. On transurethral resection of the prostate, 45 g of prostate tissue was removed. Histopathology revealed clear cells arranged in the alveolar and glandular pattern with atypical, enlarged nuclei, and prominent nucleoli. Prostatic glands with corpora amylacea were

seen entrapped between the tumor cells [Figure 1]. Based on these findings, possibilities of metastatic clear cell carcinoma from kidney, clear cell urothelial carcinoma, and renal type clear cell carcinoma of prostate were considered. His serum prostate-specific antigen (PSA) was 82 ng/ml. Computerized tomography (CT) abdomen showed no growth in the kidney and bladder. Cystoscopy done showed no mass lesion in the bladder. In view of the above findings, final diagnosis of renal type clear cell carcinoma of the prostate was made. The patient was treated with radical cystoprostatectomy with pelvic lymph node dissection. All the lymph nodes and urinary bladder showed no malignancy. Postoperatively, a contrast CT scan of the pelvis suggested no local or regional metastatic deposits. After one year of follow-up, the patient is doing well with no evidence of recurrence.

This case presented with two separate challenges; the characterization of the tumor and the subsequent clinical management. The cytological features in our case showed clear cells with atypical, enlarged nuclei, prominent nucleoli, and architectural features such as tubules and alveolar pattern immediately suggested metastatic clear cell RCC. Although RCC is the classic example of clear cell carcinoma, only two cases metastatic to the prostate have been reported in the literature. In our case, there were no clinical or radiological evidence of renal tumor and prostatic uroepithelium was normal. The renal lesions generally will be large and involves other organs such as lung and bone when metastasis occurs to the prostate.^[3] The histological features of clear cell carcinoma with high serum prostatic-specific antigen (PSA) levels substantiated the prostatic origin. In cases described by Singh *et al.* and Pal *et al.*, the serum PSA were within normal limits.^[2,3] These tumors arise from the periurethral zone with clear cells in the hypernephroid pattern (Gleason's score of 3 + 3). Immunohistochemically, they are positive for low

molecular weight cytokeratin, vimentin, EMA, and negative for high molecular weight cytokeratin and PSA.^[2,3] Such cases should be managed with radical cystoprostatectomy with pelvic lymph node dissection. Pathologists should be aware of such entity, whenever they see clear cells in prostatic malignancy. One should also differentiate from clear cell urothelial carcinoma and metastatic clear cell RCC as the treatment option varies.

**Harish S Permi, Kishan Prasad Hosapatna
Laxminarayana, Sunil Kumar Yeshvanth,
Jayaprakash K Shetty**

Department of Pathology, K S Hegde Medical Academy of
Nitte University, Mangalore, Karnataka, India

Address for correspondence: Dr. Kishan Prasad H L,
E-mail: dr_kishanpath@yahoo.com

REFERENCES

1. Pan CC, Chiang H, Chang YH, Epstein JI. Tubulocystic clear cell adenocarcinoma arising within the prostate. *Am J Surg Pathol* 2000;24:1433-6.
2. Pal DK, Chowdhury MK. Renal type clear cell carcinoma of the prostate. *Indian J Surg* 2007;69:81.
3. Singh H, Flores-Sandoval N, Abrams J. Renal-type clear cell carcinoma occurring in the prostate. *Am J Surg Pathol* 2003;27:407-10.S Teerthanath

Access this article online	
Quick Response Code: 	Website: www.jlponline.org
	DOI: 10.4103/0974-2727.86853

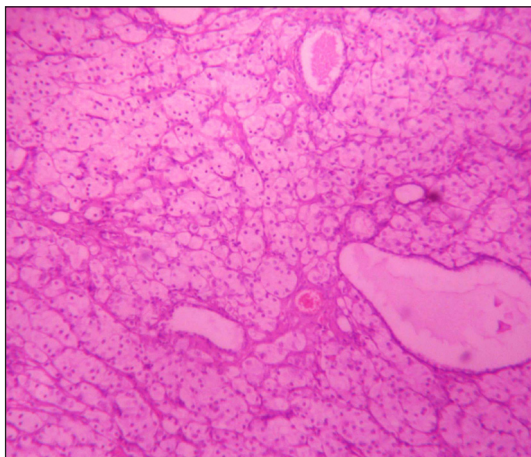


Figure 1: Clear cells in the alveolar pattern with entrapped prostatic glands (Hematoxylin and Eosin, ×100)