

Case Report

Sister Mary Joseph's nodule: A rare site for a common malignancy

Sneha Patil¹, Kratee Kratee¹, Mohammad Jaseem Hassan¹, Kafil Akhtar¹

¹Department of Pathology, Jawaharlal Nehru Medical College, Aligarh Muslim University, Aligarh, Uttar Pradesh, India.

*Corresponding author:

Kafil Akhtar,
Department of Pathology,
Jawaharlal Nehru Medical
College, Aligarh Muslim
University, Aligarh, Uttar
Pradesh, India.

drkafilakhtar@gmail.com

Received: 13 July 2024
Accepted: 30 January 2025
Epub Ahead of Print: 18 March 2025
Published: 08 April 2025

DOI
[10.25259/JLP_149_2024](https://doi.org/10.25259/JLP_149_2024)

Quick Response Code:



ABSTRACT

Sister Mary Joseph's nodule is identified by detectable lumps that extend into the umbilicus due to the spread of cancer from the abdominal or pelvic regions. Commonly, these cancers originate from the gastrointestinal or genital areas, but other sources are rare. Our case involved a 27-year-old female who came with an umbilical swelling with bilateral adnexal growth. Laboratory, radiological, and histopathological examinations led to a diagnosis of adenocarcinoma ovary, with metastasis to the umbilicus. To our knowledge, this is a rare presentation of common abdominal malignancy, and therefore, this presentation should be kept in mind for an early diagnosis and better outcome.

Keywords: Adenocarcinoma, Ovary, Sister Mary Joseph's nodule, Umbilical metastasis

INTRODUCTION

The term "Sister Mary Joseph's nodule" refers to an umbilical nodule that serves as a cutaneous metastasis originating from a primary cancer. This designation honors a nurse recognized for identifying the link between this symptom and advanced stages of cancer.^[1]

Typically, the malignancy associated with this nodule arises from adenocarcinomas in the gastrointestinal or genitourinary systems. However, sources from hematological origins, as well as pulmonary or breast cancers, are also documented.^[2] Herein, we report a case of adenocarcinoma ovary with metastasis to the umbilicus.

CASE REPORT

A 27-year-old female patient presented to the Obstetrics and Gynecology Outpatient Department with complaints of abdominal distention for the past 2–3 months, along with an umbilical nodule. Physical examination showed a moderate to grossly distended abdomen and an inflamed and ulcerated brownish-black nodule around the umbilicus measuring 2 cm × 1.5 cm with satellite nodules measuring <1 cm [Figure 1]. She also complained of multiple episodes of loose stools and nausea with abdominal pain on and off (suggestive of widespread carcinomatosis).

Serum markers of carbohydrate antigen (CA) – 125 (323.0 U/mL) and beta-human chorionic gonadotropin (858 mU/mL) were elevated. An abdominal contrast-enhanced magnetic resonance tomography showed a large solid cystic mass of size 11 × 16 × 16.5 cm in bilateral adnexa with multiple enhancing lymph nodes, the largest of size 5 × 5.5 cm along bilateral common

This is an open-access article distributed under the terms of the Creative Commons Attribution-Non Commercial-Share Alike 4.0 License, which allows others to remix, transform, and build upon the work non-commercially, as long as the author is credited and the new creations are licensed under the identical terms.

©2025 Published by Indian Association of Laboratory Physicians

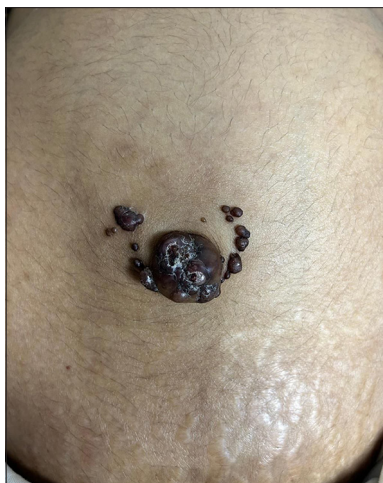


Figure 1: Clinical image showed multiple brownish-black nodules with satellite nodules around the umbilicus.

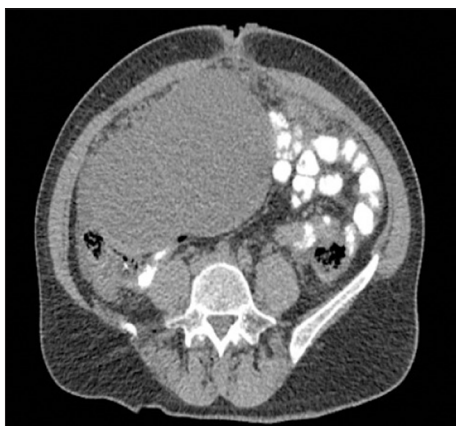


Figure 2: Contrast-enhanced magnetic resonance imaging of the abdominal cavity and pelvis showed an expansive tumorous formation covering the uterus with carcinomatosis of the peritoneum (transversal view).

iliac vessels and bilateral external iliac vessels [Figure 2]. The patient underwent ascitic fluid tap and cytology was suggestive of metastatic malignancy [Figure 3]. An umbilical skin biopsy was evaluated for pathological examination. The histopathology was suggestive of adenocarcinoma infiltrating the underlying dermis with occasional signet cells (Sister Mary Joseph's Nodule) [Figure 4]. She administered 3 weekly 3 cycles of carboplatin, 220 mg/m² and paclitaxel, 50 mg/m²-based chemotherapeutic regimen. She is doing well at 3 months of follow-up period.

DISCUSSION

Metastases to the umbilicus commonly referred to as Sister Joseph's or Sister Mary Joseph's nodule are rare but widely

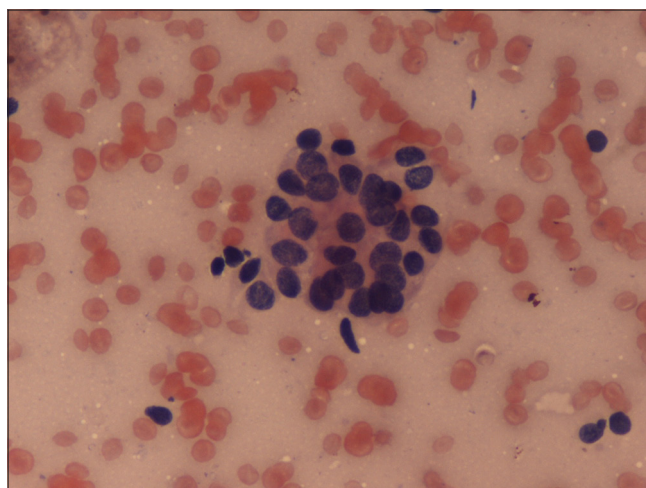


Figure 3: Fine needle aspiration cytology was suggestive of metastatic malignancy. Hematoxylin and eosin $\times 40$.

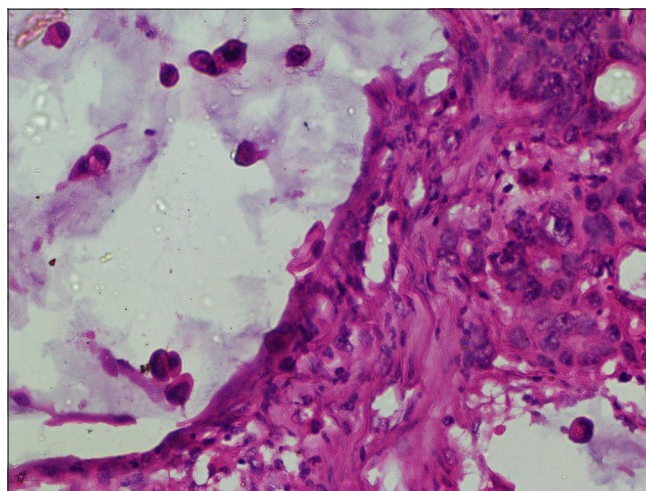


Figure 4: The histopathology was suggestive of adenocarcinoma infiltrating the underlying dermis with occasional signet cells. Hematoxylin and eosin $\times 40$.

accepted as an ominous sign of poor prognosis, with survival averaging 2–11 months from diagnosis.^[2,3]

There are three proposed mechanisms of metastasis of a neoplasm to the umbilical region – direct spread, vascular dissemination, and lymphatic propagation.^[4-6] In our case, direct peritoneal spread was most likely the cause, which was confirmed by the fact of the widespread carcinomatosis of the patient.

Clinically, Sister Mary Joseph's Nodule usually manifests as a firm, irregular nodule of about 1–1.5 cm in size but sometimes can reach 10 cm and cause pain, ulceration, and the production of various types of discharge.^[7,8] The primary malignancy associated with Sister Mary Joseph's nodule depends on the gender. In men, the first source is the stomach followed by the colon and pancreas and in women, it is the ovary followed by the endometrium, colon, and pancreas.^[9-14]

Table 1: Clinical presentations and diagnosis of different studies in literature.

Diagnosis	Primary Site	Clinical Features	Authors
Metastatic colon cancer	Colon	Ulcerated umbilical mass, weight loss, cachexia, liver metastases, Sister Mary Joseph's nodule	Kamareddy, 2023 ^[9]
Ovarian cancer	Ovary	Abdominal ascites with periumbilical pain. Rapid rise in CA-125, peritoneal carcinomatosis [18F] FDG PET/CT, Axial CT	Robinson <i>et al.</i> , 2023 ^[10]
Pancreatic adenocarcinoma	Pancreas	Small, erythematous, pus-discharging nodule Elevated CA19-9, contrast-enhanced CT	Dar <i>et al.</i> , 2023 ^[11]
Metastatic pancreatic adenocarcinoma	Pancreas	Abdominal pain, periumbilical nodules, liver metastases, progression during chemotherapy, Sister Mary Joseph's nodules	Leyrat, 2021 ^[12]
Carcinoma of cecum	Cecum	Abdominal pain, ascites, umbilical nodule, metastatic adenocarcinoma	Balakrishnan, 2015 ^[13]
Metastatic pancreatic adenocarcinoma	Pancreas	Cachexia, elevated INR, subcutaneous nodule, weight loss, liver metastases, ascites, Sister Mary Joseph's nodule	Menzies, 2015 ^[14]

CA: Carbohydrate antigen, PET: Positron emission tomography, CT: Computed tomography, [18F] FDG: 18F-Fluorodeoxyglucose, INR: International Normalized Ratio

Computed tomography or magnetic resonance imaging is performed to assess the spread of the tumor and its distribution. The differential diagnosis of Sister Mary Joseph's Nodule includes primary umbilical carcinomas, benign tumors such as pyogenic granuloma, and conditions like abscesses or umbilical hernias [Table 1].^[8] Microscopically, Sister Mary Joseph's Nodule is most likely to be caused by tumors of the adenocarcinoma subtype, although squamous cell carcinomas and signet ring cell carcinomas can also cause umbilical metastases and the latter being particularly aggressive and commonly associated with gastric cancers.^[11,12]

Treatment strategies for Sister Mary Joseph's Nodule should be tailored to each patient, considering the primary cancer, the extent of metastasis, and the resectability of the umbilical nodule.^[13,14] Despite the poor prognosis associated with umbilical metastases, a combined treatment approach of surgery and chemotherapy has been shown to improve survival rates compared to single-modality treatments.^[15,16] Overall, the survival rate for patients with treated umbilical metastases ranges from 5 to 11 months from diagnosis, with a very grave prognosis for primary gastric adenocarcinoma.^[17-19]

CONCLUSIONS

Umbilical metastasis is rare and typically manifests in the later stages of the disease, highlighting the critical need for early detection. Thorough evaluation of any umbilical lesions is essential for the timely diagnosis of underlying cancers and to increase awareness among healthcare professionals to consider this condition in the differential diagnosis upon encountering an umbilical nodule.

Author contribution: SP: Wrote the manuscript; KK: Data collection and lab work; MJH: Data and image input; KA: Final draft and review.

Ethical approval: Institutional Review Board approval is not required.

Declaration of patient consent: The authors certify that they have obtained all appropriate patient consent.

Financial support and sponsorship: Nil.

Conflicts of interest: There are no conflicts of interest.

Use of artificial intelligence (AI)-assisted technology for manuscript preparation: The authors confirm that there was no use of artificial intelligence (AI)-assisted technology for assisting in the writing or editing of the manuscript and no images were manipulated using AI.

REFERENCES

- Sethi K, Shareef N, Bloom S. The Sister Mary Joseph nodule. *Br J Hosp Med (Lond)* 2018;79:27-9.
- Gabriele R, Conte M, Egidi F, Borghese M. Umbilical metastases: Current viewpoint. *World J Surg Oncol* 2005;3:13-4.
- Urbano FL. Sister Joseph's nodule. *Hosp Physician* 2001;37:33-5.
- Pereira WA, Humaire CR, Silva CS, Fernandes LH. Sister Mary Joseph's nodule: A sign of internal malignancy. *Ann Bras Dermatol* 2011;86:118-20.
- Dhruv S, Anwar S, Polavarapu A, Kashi M, Andrawes S. Sister Mary Joseph's nodule: Where umbilicus holds the truth! *Cureus* 2021;13:13091-2.
- Zhang Z, Wang J, Huang J, Yu X. Umbilical metastasis derived from early stage rectal cancer: A case report. *World J Surg Oncol* 2014;12:82-3.
- Husein-El Ahmed H, Aneiros-Fernandez J, Arias-Santiago S, Naranjo-Sintes R. Sister Mary Joseph's nodule as a metastasis of ovarian adenocarcinoma. *Int J Dermatol* 2010;49:1045-6.
- Dubreuil A, Domp martin A, Barjot P, Louvet S, Leroy D.

- Umbilical metastasis or Sister Mary Joseph's nodule. *Int J Dermatol* 1998;37:7-13.
9. Katamreddy R, Lakkasani S, DaCosta T, Bains Y, Jayasingam R. Sister Mary Joseph nodule: A brief review. *Am J Gastroenterol* 2023;118:15-8.
 10. Robinson E, Nawwar A, Searle J, Lyburn I. Diffuse peritoneal carcinomatosis and Sister Mary Joseph nodule in ovarian carcinoma - exquisite demonstration of the peritoneal reflections on [18F]FDG PET/CT. *Nuclear Med Rev* 2023;26:153-5.
 11. Dar IH, Kamili MA, Kuchaai FA. Sister Mary Joseph nodule - A case report with review of literature. *J Res Med Sci* 2023;14:385-7.
 12. Leyrat B, Bernadach M, Ginzac A, Lusho S, Durando X. Sister Mary Joseph nodules: A case report about a rare location of skin metastasis. *Case Rep Oncol* 2021;14:664-70.
 13. Balakrishnan R, Rahman MA, Das A, Naznin B, Chowdhury Q. Sister Mary Joseph's nodule as the initial presentation of carcinoma caecum: Case report and literature review. *J Gastrointest Oncol* 2015;6:102-5.
 14. Menzies S, Chotirmall SH, Wilson G, O'Riordan D. Sister Mary Joseph nodule. *BMJ Case Reports* 2015;10:11-36.
 15. Ioannidis O, Cheva A, Stavrakis T, Paraskevas G, Papadimitriou N, Kakoutis E, *et al.* Sister Mary Joseph's nodule as the sole presenting sign of gastric signet ring cell adenocarcinoma. *Gastroenterol Clin Biol* 2010;34:565-8.
 16. Berlth F, Bollschweiler E, Drebber U, Hoelscher AH, Moenig S. Pathohistological classification systems in gastric cancer: Diagnostic relevance and prognostic value. *World J Gastroenterol* 2014;20:5679-84.
 17. Zadeh VB, Kadyan R, Al-Abdulrazzaq A, Al-Otaibi S, Sarhan A, Najem N. Sister Mary Joseph's nodule: A case of umbilical cutaneous metastasis with signet ring cell histology. *Indian J Dermatol Venereol Leprol* 2009;75:503-5.
 18. De Angeli M, Carosi M, Vizza E, Corrado G. Sister Mary Joseph's nodule in endometrial cancer: A case report and review of the literature. *J Cancer Res Ther* 2019;15:1408-10.
 19. Yoshinori I, Takashi K. A long-term survival case of Sister Mary Joseph's nodule caused by colon cancer and treated with a multidisciplinary approach. *Nagoya J Med Sci* 2019;81:325-9.

How to cite this article: Patil S, Kratee K, Hassan MJ, Akhtar K. Sister Mary Joseph's nodule: A rare site for a common malignancy. *J Lab Physicians*. 2025;17:142-5.doi: 10.25259/JLP_149_2024