



Hemolytic Disease of Newborn due to ABO Incompatibility between B Blood Group Mother and A Blood Group Neonate

Suman S. Routray¹ Debasish Mishra¹ Girija N. Kanungo¹ Rachita Behera¹

¹Department of Transfusion Medicine, Institute of Medical Sciences and SUM Hospital, Bhubaneswar, Odisha, India

Address for correspondence Debasish Mishra MD, Department of Transfusion Medicine, Institute of Medical Sciences and SUM Hospital, Bhubaneswar 751003, Odisha, India (e-mail: dr.debasish01@gmail.com).

J Lab Physicians 2023;15:146–148.

Abstract

ABO incompatibility between O blood group mother and non-O blood group neonate is common. It rarely causes anemia and hyperbilirubinemia in neonate, requiring invasive management. Direct antiglobulin test may be positive in these cases with immunoglobulin (Ig)-G antibody specificity. There are few cases of hemolytic disease of newborn due to ABO incompatibility between mother and newborn with non-O blood group mother. After obtaining consent from the patient, we reported a case of incompatibility in a B blood group mother and A blood group neonate, and it was managed with phototherapy.

Keywords

- ▶ ABO incompatibility
- ▶ direct antiglobulin test
- ▶ elution

Introduction

ABO hemolytic disease of the newborn (HDN) arises due to transplacental passage of immunoglobulin (Ig)-G antibodies of the mother with specificity for the ABO blood group system into the fetal circulation. This results in the hemolysis of fetal red blood cells, leading to fetal anemia and hyperbilirubinemia. Most commonly affected neonates are of A or B blood group with O blood group mother with immune anti-A and anti-B antibodies.¹ The quantity and subclass of maternal IgG class anti-A or anti-B that cross the placenta affect the severity of ABO HDN as each has different biological properties affecting their lytic potential.² Most of the studies on ABO hemolytic disease of newborns are restricted to O group mothers. Here, we report a case of HDN in an A blood group neonate born to a B blood group mother.

Case Report

A term male neonate weighing 2.5 kg delivered by lower section cesarian section to a B RhD-positive primigravida

mother and on exclusive breastfeeding from day 1 developed neonatal jaundice on day 4 with total serum bilirubin of 13.4 mg/dL. He was admitted to the neonatal intensive care unit on day 5 with total serum bilirubin of 17.2 mg/dL and indirect bilirubin of 16.1 mg/dL. Peripheral smear demonstrated the presence of spherocytes (++) with features suggestive of hemolysis. On complete blood count using an automated complete blood count (CBC) analyzer (semiautomatic 3-part Sysmex cell counter, model number: XP-100), hemoglobin was 17.7 g/dL with a corrected reticulocyte count of 3.2%. Thyroid profile was within normal limits. In suspicion of HDN, both mother's and neonate's blood samples were sent to the blood bank for further workup.

Forward blood grouping on neonate's blood sample with standard tube technique as per AABB technical manual demonstrated A RhD positive. Direct antiglobulin test (DAT) was positive (strength 2+) by column agglutination technique (Coombs AHG cards, Biorad, Switzerland). Monospecific DAT using IgG + C3d gel card (Tulip diagnostic (P) Ltd, Goa, India) showed IgG specificity (▶ Fig. 1). Antibody screening using 0.8% commercial cell panel (Diacell I-II-III,

article published online
July 26, 2022

DOI <https://doi.org/10.1055/s-0042-1750071>.
ISSN 0974-2727.

© 2022. The Indian Association of Laboratory Physicians. All rights reserved.

This is an open access article published by Thieme under the terms of the Creative Commons Attribution-NonDerivative-NonCommercial-License, permitting copying and reproduction so long as the original work is given appropriate credit. Contents may not be used for commercial purposes, or adapted, remixed, transformed or built upon. (<https://creativecommons.org/licenses/by-nc-nd/4.0/>)

Thieme Medical and Scientific Publishers Pvt. Ltd., A-12, 2nd Floor, Sector 2, Noida-201301 UP, India

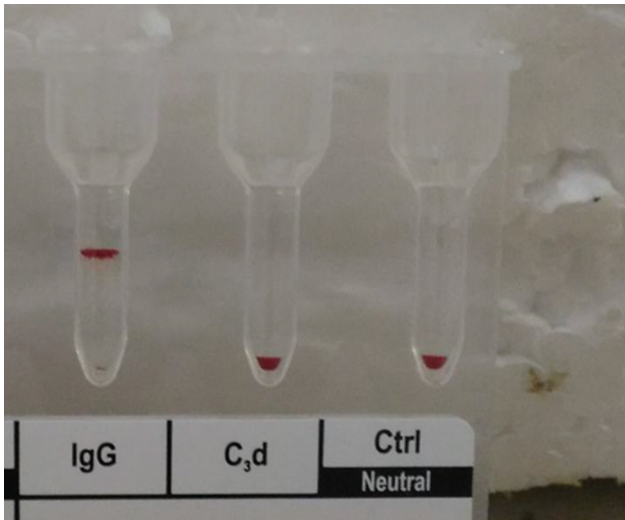


Fig. 1 Monospecific direct Coomb's test of baby red cells showing IgG positivity. Ig, immunoglobulin.

Biorad, Switzerland) by column agglutination technique was negative. Heat elution at 56°C with intermittent agitation using 6% bovine serum albumin for 10 minutes on, the DAT-positive red cells of the neonate was performed. Eluate, when tested against A1, B, and O pooled cells demonstrated the presence of anti-A which confirmed the diagnosis of ABO HDN (→ Fig. 2). Antibody screening of eluate using commercially available screening panel cells was negative. Forward and reverse grouping on the mother's blood sample was corroborative and suggestive of the B blood group. RhD typing showed agglutination (strength 4+) by tube technique. The maternal serum had high titer anti-A (IgG titer of 256), after dithiothreitol (DTT) treatment by tube technique (→ Fig. 3).

The baby received intense light-emitting diode (LED) phototherapy for 3 days and was discharged with stable vitals. On follow-up after 7 days, the total serum bilirubin was 2.8 mg/dL and the baby was doing well.

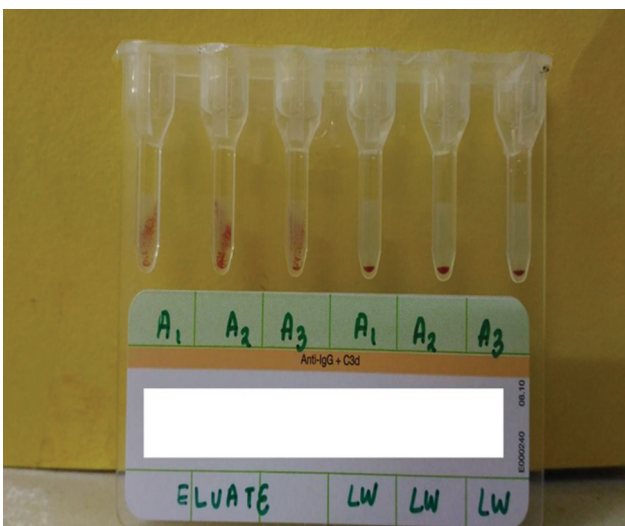


Fig. 2 Eluate of baby red cells, along with control tested with three 5% A1 cell suspension.

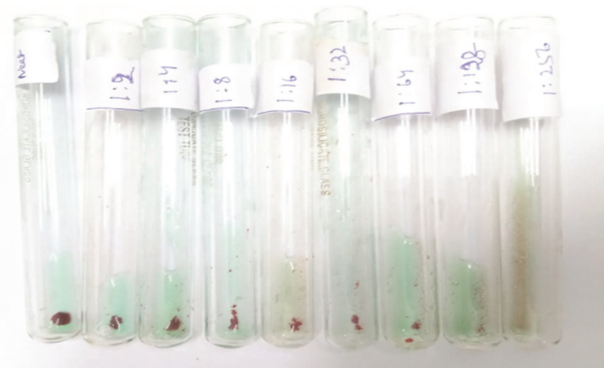

Fig. 3 Titer of mother of DTT treated serum with 5% pooled A1 cell suspension. DTT, dithiothreitol.

Discussion

Serological ABO HDN is a relatively common event with O-A/O-B incompatibility between mothers and newborns due to naturally occurring IgG isoagglutinin in group O individuals. Mostly, it is benign, often self-limiting due to the wide distribution of A and B antigens. Moreover, the A and B antigens are weakly expressed over neonates RBC resulting in a mild form of the disease. But, few cases with severe conditions requiring treatment in phototherapy, exchange transfusion, intravenous IG (IVIg) or recombinant human erythropoietin have also been reported.^{3,4} Here, we described a case of ABO HDN with B-A incompatibility between mother and newborn, requiring phototherapy.

Heterospecific ABO pregnancy accounts for 10 to 20% of all pregnancies of which only 10 to 25% manifests as HDN.^{5,6} ABO HDN emerged as a significant cause for exchange transfusion in many countries.^{7,8} Still, it is not a well-recognized entity in India because of a milder course of the disease. It is often underreported and misdiagnosed as physiological jaundice due to many centers' lack of advanced immunohematological work. In suspicion of HDN, most of the centers rely on DAT for evaluation of immune causes. In our case, DAT was positive, eluate test confirmed presence of maternal antibody along with high maternal titer which ruled out that the jaundice was due to physiological cause. But negative results do not rule out immune causes of HDN. More sensitive tests like heat elution or the Lui's freeze technique can help in negative DAT for better diagnosis of ABO HDN.⁹

As maternal IgG titers for anti-A and anti-B are not routinely performed, identifying fetuses at risk of ABO HDN is often missed during antenatal screening. Moreover, a high titer of IgG anti-A or anti-B in non O blood group mothers can even result in severe HDN, often necessitating phototherapy and IVIg.^{10,11} A maternal titer of 128 to 256 have odds of developing ABO HDN is more than two times as compared with a titer of 64 or less. Besides a titer of more than 512 is associated with invasive treatment for ABO HDN.¹² A study from South India reported 9.6 and 5.5% of group O healthy donors to have high titer (> 256) IgG antibodies of anti-A and anti-B, respectively. Moreover, the study also stated a decrease in median IgM antibody

titers with the increasing age. The vegetarian diet was also found to be more associated with the increased titers.¹³ India, catering a large population of vegetarian, data on the prevalence of IgG antibodies across different blood groups of Indian females are minimal. Timely identification of such mothers will enable us to detect fetuses at risk of ABO HDN.

Conclusion

This case report highlights the ABO HDN may not be always benign as perceived. It should also be suspected in a neonate present with features of HDN born to non-O group mother. A combination of tests like DAT, elution, peripheral blood film feature, retic count with a high degree of clinical suspicion aids in evaluating multifaceted ABO HDN.

Conflict of Interest

None declared.

References

- 1 Akanmu AS, Oyedeji OA, Adeyemo TA, Ogbenna AA. Estimating the risk of ABO hemolytic disease of the newborn in Lagos. *J Blood Transfus* 2015;2015:560738
- 2 Peevy KJ, Wiseman HJ. ABO hemolytic disease of the newborn: evaluation of management and identification of racial and antigenic factors. *Pediatrics* 1978;61(03):475-478
- 3 Jain A, Malhotra S, Marwaha N, Kumar P, Sharma RR. Severe ABO hemolytic disease of fetus and newborn requiring blood exchange transfusion. *Asian J Transfus Sci* 2018;12(02):176-179
- 4 Haque KM, Rahman M. An unusual case of ABO-haemolytic disease of the newborn. *Bangladesh Med Res Counc Bull* 2000; 26(02):61-64
- 5 Usha KK, Sulochana PV. Detection of high risk pregnancies with relation to ABO haemolytic disease of newborn. *Indian J Pediatr* 1998;65(06):863-865
- 6 Matteocci A, De Rosa A, Buffone E, Pierelli L. Retrospective analysis of HDFN due to ABO incompatibility in a single institution over 6 years. *Transfus Med* 2019;29(03):197-201
- 7 Bujandric N, Grujic J. Exchange transfusion for severe neonatal hyperbilirubinemia: 17 years' experience from Vojvodina, Serbia. *Indian J Hematol Blood Transfus* 2016;32(02):208-214
- 8 Sabzehei MK, Basiri B, Shokouhi M, Torabian S. Complications of exchange transfusion in hospitalised neonates in two neonatal centers in Hamadan, a five-year experience. *Journal of Comprehensive Pediatrics*. 2015;6(02):
- 9 Routray SS, Behera R, Mallick B, et al. The spectrum of hemolytic disease of the newborn: evaluating the etiology of unconjugated hyperbilirubinemia among neonates pertinent to immunohematological workup. *Cureus* 2021;13(08):e16940
- 10 Wang R, Li Y, Tong Y, Su N. Hemolytic disease of the fetus and newborn caused by anti-group A IgG from a group B mother. *J Pediatr Hematol Oncol* 2021;43(06):e785-e787
- 11 Schooley N, Chabra S, Stolla M. From A to AB: A Caucasian mother with high anti-B titer causing hemolytic disease of the newborn. *Lab Med* 2022;53(02):e33-e35
- 12 Li P, Pang LH, Liang HF, Chen HY, Fan XJ. Maternal IgG anti-A and anti-B titer levels screening in predicting ABO hemolytic disease of the newborn: a meta-analysis. *Fetal Pediatr Pathol* 2015;34(06):341-350
- 13 Kannan S, Kulkarni R, Basavarajegowda A. Prevalence of high titered anti-A and anti-B antibodies among O blood group individuals and their associated factors. *Global Journal of Transfusion Medicine*. 2020;5(02):187