



# A Case Series of Fetal-Neonatal Ovarian Cyst from a Tertiary Care Hospital

Priyadarshini Kumaraswamy Rajeswaran<sup>1</sup> Shanthakumari Sivanandam<sup>1</sup> Pavai Arunachalam<sup>2</sup>

<sup>1</sup>Department of Pathology, PSG Institute of Medical Sciences, Coimbatore, Tamil Nadu, India

<sup>2</sup>Department of Paediatric Surgery, PSG Institute of Medical Sciences, Coimbatore, Tamil Nadu, India

Address for correspondence Priyadarshini Kumaraswamy Rajeswaran, MBBS, MD, Department of Pathology, PSG Institute of Medical Sciences, Off Avinashi Road, Peelamedu, Coimbatore, Tamil Nadu 641004, India (e-mail: drpriyadarshini.kr@gmail.com).

J Lab Physicians 2023;15:596–601.

## Abstract

The occurrence of ovarian cyst in the neonate is rare and antenatally diagnosed by ultrasonography. This study aims to increase awareness about its occurrence and histological features. We performed a retrospective review on 10 cases of neonatal ovarian cyst (NOC) during 4 years (2016–2020) in a tertiary care center in South India. The neonates were diagnosed with abdominal cysts by the antenatal ultrasonogram in the third trimester. They were operated from day 5 to 35 days of age. There was no side predilection, and most of them were unilateral (9 out of 10 cases). Histopathological examination showed simple cysts (50%), serous cystadenomas (20%), cyst with no viable lining (20%), and follicular cyst (10%) and 90% of the cysts had torsion-induced changes. The pathologist and the clinician should be aware of the occurrence of serous histology in NOC cases.

## Keywords

- ▶ neonatal ovarian cyst
- ▶ serous cystadenoma
- ▶ torsion

## Introduction

The occurrence of ovarian cyst in a neonate is rare, and the reported incidence is 1 in 2,625 pregnancies.<sup>1,2</sup> The first case was reported in 1889 as an autopsy finding in a premature stillborn fetus.<sup>1</sup> The most frequent and severe complication is torsion, followed by hemorrhage, autoamputation, rupture, hydrops, dystocia, and pressure on adjacent organs.<sup>2</sup> The recommended treatment for symptomatic cases is surgical excision. Histologically, the neonatal ovarian cyst (NOC) has flattened to the single layer of cuboidal lining. Nevertheless, nearly 20% of cases turn out as serous cystadenoma, a benign neoplasm.<sup>2–5</sup> Awareness of serous cystadenoma in the neonate is essential for the pathologists to diagnose and the clinicians to treat it.

Therefore, this study aims to analyze retrospectively the specimens received in this part of the country for a better patient outcome.

## Materials and Methods

All reported cases of NOCs received were retrieved from the archives of the department of pathology and analyzed for clinical presentation and pathological diagnosis over 4 years from January 2016 to December 2020. The blocks and slides were retrieved, sections cut, stained with hematoxylin and eosin, and analyzed.

## Results

We retrieved 10 cases from the archives, and the results are shown in ▶ **Tables 1** and **2**.

Cyst excision in the neonates was from 5 to 35 days with a mean age of 20 days. Ninety percent of the excision was for torsion (9/10 cases). All cases were antenatally diagnosed between 32 and 36 weeks of gestation by ultrasonogram. The

received  
January 31, 2023  
accepted after revision  
April 13, 2023  
article published online  
June 13, 2023

DOI <https://doi.org/10.1055/s-0043-1768947>.  
ISSN 0974-2727.

© 2023. The Indian Association of Laboratory Physicians. All rights reserved.

This is an open access article published by Thieme under the terms of the Creative Commons Attribution-NonDerivative-NonCommercial-License, permitting copying and reproduction so long as the original work is given appropriate credit. Contents may not be used for commercial purposes, or adapted, remixed, transformed or built upon. (<https://creativecommons.org/licenses/by-nc-nd/4.0/>)

Thieme Medical and Scientific Publishers Pvt. Ltd., A-12, 2nd Floor, Sector 2, Noida-201301 UP, India

**Table 1** The clinical and ultrasound features of 10 NOC cases

Case no.	Age at USG diagnosis (wk)	Side	Birth weight (kg)	USG diagnosis	Material risk factor or comorbidities	Clinically mass palpable	Mode of delivery	Term of delivery	Associated other congenital anomalies	Consanguinity
1	32	Right	4	Duplication/Ovarian cyst	Nil	No	Emergency LSCS due to fetal distress	Term	Nil	Nonconsanguineous
2	30	Left	3.5	Ovarian cyst	Nil	No	NVD	Term	Nil	Nonconsanguineous
3	33	Left	2.9	Mesenteric/duplication/ovarian cyst	Nil	Yes 6 × 6 cm	NVD	Term	Nil	Consanguineous
4	35	Left	2.6	Mesenteric/duplication/ovarian cyst	Nil	Yes 5 × 3 cm	NVD	Term	Nil	Nonconsanguineous
5	32	Left	3.9	Ovarian dermoid	Hypothyroidism	Yes 5 × 5 cm	NVD	Term	Nil	Nonconsanguineous
6	34	Right	2.8	Enteric duplication cyst	Nil	No	NVD	Term	Nil	Nonconsanguineous
7	38	Left	2.6	Complex ovarian cyst/enteric duplication cyst	Nil	No	NVD	Term	Nil	Nonconsanguineous
8	32	Right	2.9	Duplication cyst	Rh incompatibility	No	NVD	Term	Nil	Consanguineous
9	36	Bilateral	2.6	Ovarian cyst	Nil	Yes 5 × 5 cm	LSCS	Term	Nil	Nonconsanguineous
10	32	Right	3.3	Ovarian cyst	Nil	Yes 4 × 3 cm	NVD	Term	Nil	Consanguineous

Abbreviations: LSCS, lower segment caesarean section; NOC, neonatal ovarian cyst; NVD, normal vaginal delivery; USG, ultrasonogram.

**Table 2** The surgical management and pathological features of 10 NOC cases

Case no.	Age at cyst excision (d)	Gross cyst size (GD in cm)	Length of the pedicle (cm)	Mode of cyst excision	Complication evidenced on clinical and/or pathological examination	Type of cyst on microscopy
1	8	4	0.5	Laparoscopic excision after cyst aspiration	Torsion and pressure effects	Simple ovarian cyst with extensive infarction
2	35	4.8	0.3	Laparoscopic excision after cyst aspiration	Torsion	Ovarian cyst with no viable epithelial lining and with areas of calcification and infarct
3	5	5.5	0.4	Laparoscopic excision after cyst aspiration	Nil	Follicular cyst
4	30	4	0.6	Laparoscopic cyst excision	Torsion	Ovarian cyst with no viable epithelial lining and torsion induced changes
5	33	4.5	0.8	Laparoscopic cyst excision after aspiration	Torsion and pressure effects	Simple ovarian cyst with features of torsion and extensive calcification
6	10	4	0.4	Laparoscopic cyst excision after aspiration	Torsion	Simple ovarian cyst with torsion induced changes
7	20	5	0.5	Laparoscopic cyst excision after aspiration	Torsion	Serous cystadenoma with torsion induced changes
8	30	5	0.7	Laparoscopic cyst excision after aspiration	Torsion	Simple ovarian cyst with torsion induced changes
9	17	4 (Right) 1.8 (Left)	0.5	Right – cyst excision only Left – only cyst fluid aspiration	Torsion	Simple ovarian cyst with torsion induced changes
10	11	3.5	0.6	Laparoscopic excision	Torsion and autoamputation	Serous cystadenoma with torsion induced changes

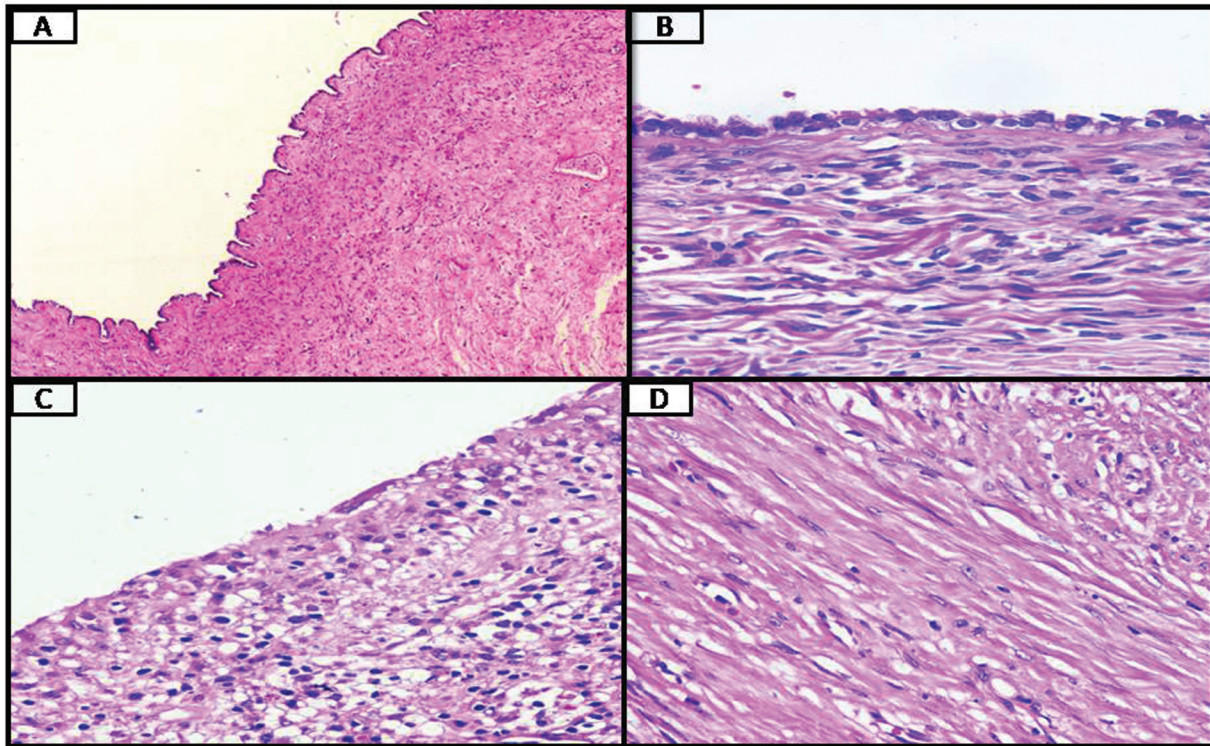
Abbreviation: NOC, neonatal ovarian cyst.

neonates were diagnosed with intra-abdominal cyst between 30 and 38 weeks of gestational age by antenatal ultrasonography. There was no side predilection for the cyst occurrence, with one neonate having bilateral cysts. The size of the cyst varied from 1.8 to 5.5 cm in the greatest dimension. The most common complication of NOC was torsion (90%), two cases (20%) had pressure effects, and one case (10%) had autoamputation.

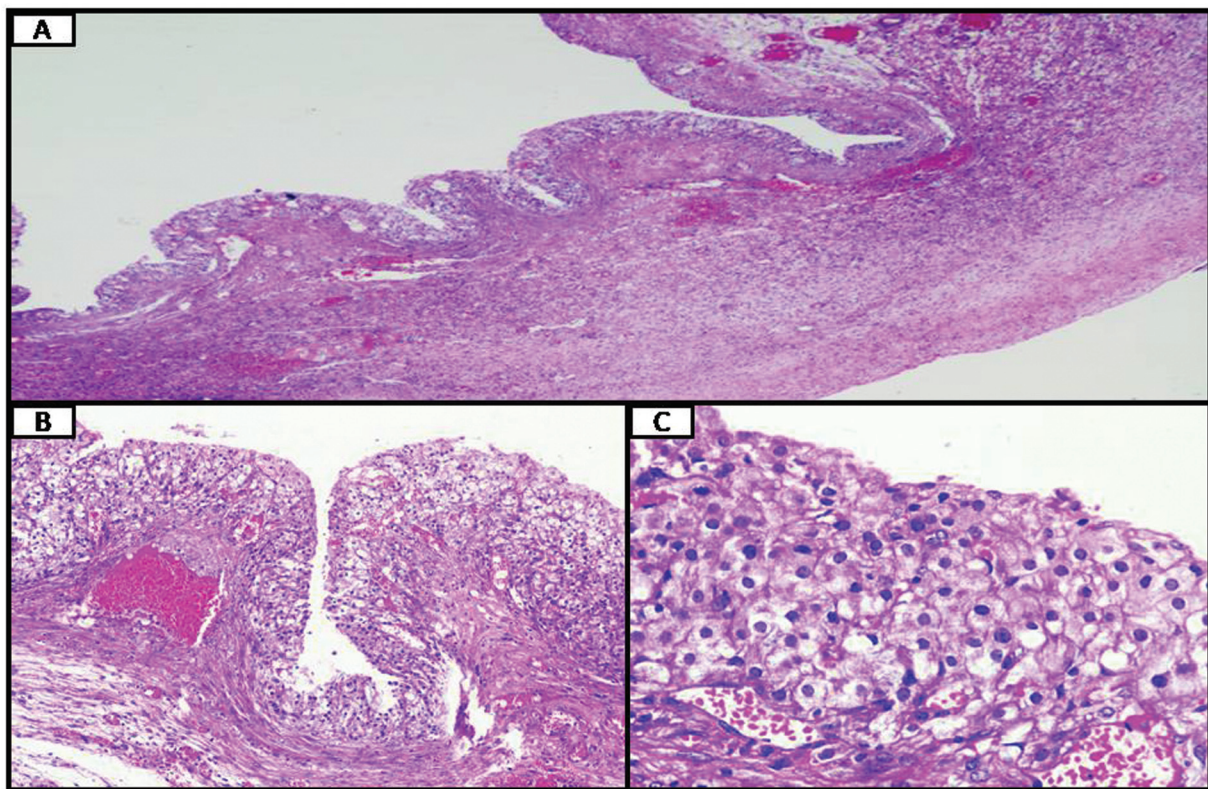
Histologically, simple cyst was found in 5 neonates (50%), serous cystadenoma in 2 neonates (20%), with no viable lining in 2 cysts (20%), and 1 case (10%) was of follicular origin (►Table 2, ►Figs. 1 and 2). These cysts most often had hemorrhage, calcification, and necrosis (►Fig. 3).

## Discussion

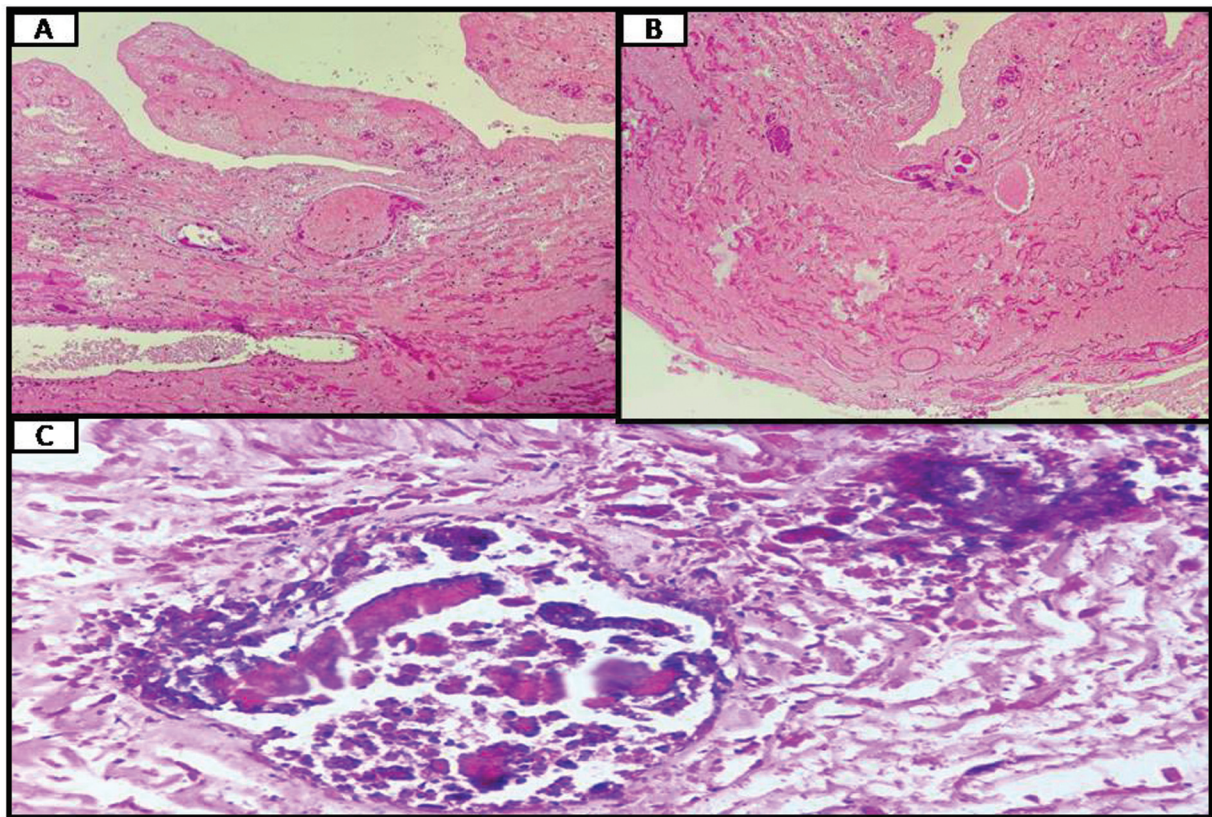
NOC is frequently diagnosed in the third trimester by antenatal ultrasonography. The first case was described in 1889 as an autopsy finding in a premature stillborn fetus.<sup>1</sup> In an autopsy study of 233 neonatal deaths and stillborn by deSa,<sup>6</sup> small ovarian cysts were found in 34%. The age at diagnosis by ultrasonography ranged from 24 to 39 weeks of gestation in a study by Monnery-Noché et al.<sup>7</sup> The literature search shows the early age of diagnosis by ultrasonography at 19 weeks<sup>3,8</sup> of gestation. The cyst size is variable, and the largest cyst found in the literature measured 20 cm in diameter.<sup>8</sup> The cysts are predominately unilateral, and bilateral cysts are rare, with only a few cases reported.<sup>5,8,9</sup>



**Fig. 1** Histological lining of some cases of NOC studied in our case series (A) Photomicrograph of a simple ovarian cyst wall with single layer of flattened to cuboidal benign epithelial lining (H & E stain, 10x). (B) Photomicrograph of a benign serous cystadenoma ovarian cyst wall with single layer of benign columnar epithelial lining with cilia (H & E stain, 40x). (C) Photomicrograph of a simple ovarian cyst wall with denuded lining epithelium (H & E stain, 40x). (D) Photomicrograph of the cyst wall which has fibrocollagenous stroma with few lymphocytes and capillaries (H & E stain, 40x).



**Fig. 2** A case of follicular neonatal ovarian cyst. (A) Photomicrograph of a cyst wall with cyst lined by several layers of cells in low power (hematoxylin and eosin [H&E] stain, 40x). (B) Cyst wall lining composed of an inner layer of granulosa cells and an outer layer of luteinized theca cells (H&E stain, 10x). (C) Theca cells contains eosinophilic to clear cytoplasm and round nuclei with prominent central nucleoli (H&E stain, 10x).



**Fig. 3** Histological changes seen due to complications in neonatal ovarian cyst. (A and B) Photomicrograph of a cyst wall with hemorrhage and necrosis (hematoxylin and eosin [H&E] stain, 10 ×). (C) Photomicrograph of a cyst wall with focal calcification (H&E stain, 40 ×).

The etiopathogenesis of NOC remains unknown. The stimulus for the cyst formation is attributed to increased placental human chorionic gonadotrophin (HCG)<sup>1,3,8-11</sup> in conditions such as maternal diabetes, toxemia of pregnancy, and Rh incompatibility causing hyperstimulation of the normal ovarian follicle to undergo cystic change. In our study, one mother had Rh incompatibility, and one mother had hypothyroidism. The presence of fetal prematurity, congenital adrenal hyperplasia, and hypothyroidism<sup>1,9,10</sup> are also found to cause NOC as they are associated with greater sensitivity to HCG. Literature survey revealed NOC also occurs in healthy mothers often.<sup>11</sup>

Though serous cystadenomas constitute approximately 40% of all ovarian tumors occurring in the reproductive age group,<sup>12</sup> it is infrequent in the fetus. From the literature search, only three studies<sup>3-5</sup> have reported serous cystadenoma among the NOC. The etiological reasons for the occurrence of serous cystadenoma in neonates are not known. Our study found the incidence of serous cystadenoma to be 20%, similar to other studies. The pathologist should also consider the diagnosis of the surface epithelial tumor as a differential diagnosis of NOC.

The most common dreaded complication of these NOCs is torsion (50–78%)<sup>2,9,13,14</sup> and are found to occur most frequently during fetal life than in the postnatal period,<sup>9</sup> which is also evidenced in this case series. Certain studies<sup>9</sup> point out the risk of torsion, which depends on the cyst's size (frequently seen in cysts of size > 4 cm) and the length of the

pedicle.<sup>3</sup> At the same time, there are studies<sup>7,15</sup> that state that the risk of developing torsion is not dependent on the size of the cyst or age of the neonate. Among the 10 cases presented here, 9 cases had features of torsion. Our study also infers that the torsion of the ovarian cysts in neonates is not dependent on the cyst size.

The other complications<sup>2,9</sup> of NOC are rupture, hemorrhage, perforation, intestine and urinary tract obstruction, pulmonary hypoplasia, dystocia, autoamputation,<sup>10</sup> adhesion, calcification of cyst wall,<sup>3</sup> and sterile necrosis of the ovary. We had two neonates with intestinal and urinary obstruction symptoms and an intraoperative observation of an autoamputation of an ovarian cyst. There were 9 out of 10 cases with microscopic evidence of calcification as noted in other studies.<sup>1,4,14</sup>

Controversy prevails regarding the management of NOC. Since most of them regress in the postnatal period, conservative management is suggested even for cysts with sizes of 5 cm.<sup>3,8</sup> Intrauterine ovarian cyst aspiration<sup>3,16</sup> can be performed, but it has complications such as rupture, hemorrhage, and infection. Laparoscopy excises cyst with complications or large size. From our study, we infer that 20% of cases are neoplastic, and therefore removal of NOC should be considered at the earliest with a follow-up even though there are no complications.

As surgery is the primary treatment for ovarian tumors, ovarian salvage with fertility preservation in the unilateral cyst is important since single ovary presence renders them a

short reproductive life span.<sup>7</sup> Minimally invasive surgical technique is essential for the cysts occurring in a neonate. Follow-up using serial ultrasonography<sup>14</sup> is vital to look for regression or development of complications such as torsion.

A study by Gaspari et al<sup>17</sup> points out the occurrence of NOC as an early manifestation of McCune–Albright syndrome, which enables early diagnosis in such cases.

In summary, NOC is commonly diagnosed nowadays due to the increased usage of antenatal ultrasonography. The etiology is variable. The common complication is torsion. Histologically, the most common is a simple cyst with 20% incidence of serous ovarian cystadenoma. Increased awareness of the occurrence of serous cystadenoma is vital for pathologists to be able to consider it as a differential diagnosis in NOC. The management of the NOC is controversial, mainly by laparoscopy excision.

### Limitation

The limitation of this study is further clinical follow-up of the neonates could not be done since they have not come for further follow-up at the center.

**Conflict of Interest**  
None declared.

### References

- Mudholkar VG, Acharya AS, Kulkarni AM, Hirgude ST. Antenatally diagnosed neonatal ovarian cyst with torsion. *Indian J Pathol Microbiol* 2011;54(01):228–229
- Erol O, Erol MB, Isenlik BS, Ozkiraz S, Karaca M. Prenatal diagnosis of fetal ovarian cyst: case report and review of the literature. *J Turk Ger Gynecol Assoc* 2013;14(02):119–122
- Akın MA, Akın L, Özbek S, et al. Fetal-neonatal ovarian cysts—their monitoring and management: retrospective evaluation of 20 cases and review of the literature. *J Clin Res Pediatr Endocrinol* 2010;2(01):28–33
- Manjiri S, Padmalatha SK, Shetty J. Management of complex ovarian cysts in newborns - our experience. *J Neonatal Surg* 2017;6(01):3
- Taits AN, Ivanov DO, Reznik VA, et al. Experience of diagnostics and treatment of infants with ovarian masses. *Int J Pregn & Child Birth* 2019;5(01):1–3
- deSa DJ. Follicular ovarian cysts in stillbirths and neonates. *Arch Dis Child* 1975;50(01):45–50
- Monnery-Noché ME, Auber F, Jouannic JM, et al. Fetal and neonatal ovarian cysts: is surgery indicated? *Prenat Diagn* 2008;28(01):15–20
- Widdowson DJ, Pilling DW, Cook RC. Neonatal ovarian cysts: therapeutic dilemma. *Arch Dis Child* 1988;63(7 Spec No):737–742
- Ogul H, Havan N, Pirimoglu B, Guvendi B, Kisaoglu A, Kantarci M. Prenatal and postnatal ultrasonographic findings of the torsioned ovarian cyst: a case report and brief literature review. *Int Surg* 2015;100(03):514–517
- Jain M, Pujani M, Madan NK, Chadha R, Puri A. Congenital ovarian cyst: a report of two cases. *J Lab Physicians* 2012;4(01):63–65
- Ibrahim H, Lewis D, Harrison GK, Tice H, Sangster G. Congenital ovarian cyst. *J Perinatol* 2007;27(08):523–526
- Katke R. Rare presentation of serous cystadenoma as hemorrhagic cyst. *Obstet Gynecol Int J* 2015;2:1–3
- Jafri SZ, Bree RL, Silver TM, Ouimette M. Fetal ovarian cysts: sonographic detection and association with hypothyroidism. *Radiology* 1984;150(03):809–812
- Bharambe B, Bolde S, Bharti S, Somani N. A case series of congenital ovarian cyst in a Tertiary Care Hospital in Mumbai, India. *Ann Pathol Laborat Med* 2017;4:C56–C58
- Nussbaum AR, Sanders RC, Hartman DS, Dudgeon DL, Parmley TH. Neonatal ovarian cysts: sonographic-pathologic correlation. *Radiology* 1988;168(03):817–821
- Tehrani F, Kavehmanesh Z, Kaveh M, Tanha F. Neonatal ovarian cyst: a case report. *Iran J Pediatr* 2007;17(03):379–382
- Gaspari L, Paris F, Nicolino M, et al. Fetal ovarian cysts: an early manifestation of McCune–Albright syndrome? *Prenat Diagn* 2012;32(09):859–863