



Posttreatment Persistence of Monoclonal Protein on Immunofixation Electrophoresis but Absence on Serum Protein Electrophoresis in a Case of Solitary Bone Plasmacytoma

Visesh Kumar¹ Priti Rani¹ Neha Rai¹ Subhash Kumar² Mala Mahto¹

¹Department of Biochemistry, All India Institute of Medical Sciences, Patna, Bihar, India

²Department of Radiodiagnosis, All India Institute of Medical Sciences, Patna, Bihar, India

Address for correspondence Mala Mahto, MD, Department of Biochemistry, AIIMS, Patna, Bihar 801507, India (e-mail: dr.malamahto@gmail.com).

J Lab Physicians 2023;15:162–165.

Abstract

Laboratory investigations for any suspected case of solitary plasmacytoma of bone include routine biochemical and hematological investigations along with β 2-microglobulin, electrophoresis of serum protein and/or 24-hour urine protein, serum protein immunofixation (IFE), and nephelometric quantification of total immunoglobulin isotype and serum free light chain levels. Bone marrow aspirate and trephine biopsy are mandatory to confirm the absence of clonal plasma cells (for solitary plasmacytoma) or the presence of less than 10% clonal cells (solitary plasmacytoma with minimal bone marrow involvement). Imaging studies such as X-ray, computed tomography (CT), magnetic resonance imaging, and positron emission tomography/CT should be used to complement laboratory tests in diagnosis, staging, and defining the local extent of the plasmacytoma. However, guidelines regarding choice of technique for the detection of M band when monitoring a follow-up case of operated plasmacytoma are still not clear. Through this case study, we try to highlight the role of IFE in a follow-up case of operated solitary plasmacytoma of the bone.

Keywords

- ▶ plasmacytoma
- ▶ serum protein electrophoresis
- ▶ serum immunofixation

Introduction

The solitary plasmacytoma (SP) is defined as a localized accumulation of neoplastic monoclonal plasma cells without systemic manifestations. It is a rare form of plasma cell neoplasm accounting for 5 to 10% of all plasma cell dyscrasias.¹ The diagnosis of solitary bone plasmacytomas (SBPs) requires solitary bone lesion confirmed by skeletal survey, plasma cell infiltration proven by biopsy, normal bone

marrow (BM) biopsy, that is, less than 10% plasma cells, and lack of myeloma defining events.² According to Durie and Salmon staging system, SBPs are regarded as stage I myeloma satisfying all of the following criteria: hemoglobin greater than 10 g/dL, normal level of serum calcium, normal bone structure or SP only, and low M-component (immunoglobulin G [IgG] < 5 g/dL, IgA < 3 g/dL, urine light chains < 4 g/24 hours).^{2,3} Skeletal survey, computed tomography, and magnetic resonance imaging may also be helpful to

article published online
July 26, 2022

DOI <https://doi.org/10.1055/s-0042-1750080>.
ISSN 0974-2727.

© 2022. The Indian Association of Laboratory Physicians. All rights reserved.

This is an open access article published by Thieme under the terms of the Creative Commons Attribution-NonDerivative-NonCommercial-License, permitting copying and reproduction so long as the original work is given appropriate credit. Contents may not be used for commercial purposes, or adapted, remixed, transformed or built upon. (<https://creativecommons.org/licenses/by-nc-nd/4.0/>)

Thieme Medical and Scientific Publishers Pvt. Ltd., A-12, 2nd Floor, Sector 2, Noida-201301 UP, India

determine the multiple vertebra lesions or BM disease. The presence of serum monoclonal protein (MP) at the time of diagnosis has no prognostic value in SP but persistence of the serum MP posttreatment is a prognostic factor for progression to multiple myeloma (MM).^{4,5} However, there is no definitive consensus regarding the methodology to be adopted for detection of MP in follow-up cases. Various methodologies with varying sensitivities exist currently, like serum and urine protein electrophoresis (SPE/UPE), serum and urine immunofixation (IFE), serum-free light chains (sFLC), and immunoglobulin quantification for MP detection. Here we present a case of operated SBP where MP was detected on serum IFE but not on SPE. This calls for a clear guideline regarding methodology to be adopted for assessing the MP load for prognosticating SBP upon diagnosis and during follow-up posttreatment.

Case Presentation

A serum sample of a 30-year old female was received in the Biochemistry Central laboratory for SPE, which revealed no M band. However, IFE revealed presence of monoclonal lambda light chain (►Fig. 1). Relevant routine biochemical and hematological investigations were within normal limits. On interrogating the patient it was revealed that she was a known case of L5 operated plasmacytoma in March 2021. Histopathological examination report of a sample revealed plasma cell neoplasm. Frozen section report revealed plasmacytoma. Immunohistochemistry revealed CD138 diffuse positivity in tumor cells. Tumor cells showed lambda light

chain restriction. MIB-1 labeling index was 10 to 12%. She was at that time undergoing radiotherapy in our hospital.

Discussion

Plasmacytoma is a malignant neoplasm of monoclonal B cells first described by Schridde in 1905.⁶ It is a rare condition with a cumulative incidence of 0.15/100.⁷ It consists of three distinct entities according to International Myeloma Working Group, 2003: SP of bone (SPB), extramedullary plasmacytoma (EMP), and multiple primary or recurrent plasmacytomas.⁸

SP refers to single isolated involvement of bone or soft tissue by neoplastic monoclonal plasma cells with no additional clinical, radiological, laboratory, and BM evidence of plasma cell dyscrasia. SPB commonly affects in the 5th and 6th decades with a male preponderance and involvement of axial skeleton commonly as a single osteolytic lesion.^{8,9}

SPB comprises 70% of all SP cases and occurs primarily in vertebrae, femurs, pelvis, and ribs.¹⁰ Patients with SPB with minimal BM plasmacytosis have a higher risk of developing symptomatic MM: approximately 50% of patients with SPB and 30% of patients with EMP develop MM within 10 years of initial diagnosis.¹ The presence of serum MP at the time of diagnosis has no prognostic value in SP. Conversely, persistence of the serum MP after radiation therapy is a prognostic factor for progression to MM.^{4,5} In a study by Agbuduwe et al, a serum paraprotein was detectable in 18 out of 27 (53%) patients of SPB at the time of diagnosis.¹¹ Wilder et al reported a 10-year progression-free survival of 29% in patients with SPB whose serum MP persisted after radiotherapy, compared with 91% in patients whose serum MP disappeared.¹² Not only the presence of serum MP but also its levels yield prognostic information in SPB. Dingli et al proposed a prognostic scoring method incorporating an abnormal sFLC ratio and a persistent serum MP level greater than 0.5 g/dL as adverse prognostic factors.¹³ As plasmacytoma is a rare entity with very less data in the form of prospective studies, the evidence for the current management of SP is mainly based on relatively small retrospective studies. Bone localization, age greater than 60 years, persistence of a paraprotein after 1 year of therapy, and an abnormal sFLC ratio at diagnosis have been associated with an increased risk of progression to MM while tumor size less than 5 cm was reported to be a favorable factor.¹¹

MP detection is possible by SPE and UPE, serum and urine IFE, immunoglobulin quantification by nephelometry, and sFLC assay for monoclonal excess of any one light chain. In a study by Chang et al, 69 patients with SP and SP with minimal BM involvement were reviewed retrospectively to identify the clinical usefulness of serum MP and to establish a rationale for regular follow-up with SPE in SP. Their findings revealed that patients who had persistence of serum MP posttreatment showed worse MMFS (5-year MM-free survival) and FFS (5-year failure-free survival) compared with those whose serum MP disappeared or who had nonsecretory disease initially. The increase of serum MP level 0.1 g/dL or higher from the current nadir was predictive of treatment

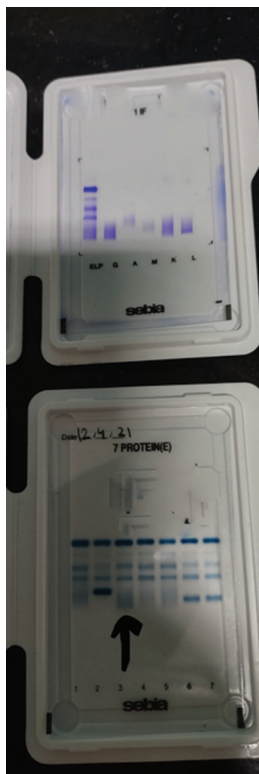


Fig. 1 Case 1: Figure showing serum protein electrophoresis and immunofixation findings in the postoperative period.

failure. Therefore, they highly recommended regular follow-up with SPE after the treatment of SP to monitor response to treatment and predict treatment failure.¹⁴

The updated recommendations of a panel of expert European hematologists with expertise in MM published in 2018 that persistence of a serum MP (determined by SPE and IFE) after initial radiation therapy predicts a higher risk of progression to MM. Therefore, it is mandatory to monitor SPE and IFE after treatment completion.¹⁰ However, the same has not been incorporated in National Comprehensive Cancer Network guidelines for plasmacytoma.

With reference to the case described above and similar findings in few other cases of plasmacytomas noted at our hospital, a common finding observed was the absence of M band on SPE but presence on IFE. This finding becomes more relevant in settings of low tumor burden where the limit of detection of MP by SPE poses a limitation. The detection limit is up to 0.3 to 0.5 gm/dL in the γ region and up to 0.7 gm/dL in the α and β regions by SPE. However, 18 to 20% of the patients with light chain MM, 1 to 3% of nonsecretory MM cases, and 15 to 20% of oligo-secretory cases show a negative result on SPE. SPE also does not comment on the antibody isotype involved. However, quantification of M band is possible by tangent skimming or perpendicular drop. IFE is performed with antisera to IgG, IgA, IgM, total kappa, and total lambda. IFE has an improved sensitivity (limit of detection of \sim 10 mg/dL) when compared with SPE (limit of detection of 100 mg/dL). Therefore, a negative SPE result does not entirely rule out a monoclonal gammopathy (MG) and should be followed by IFE.¹⁵ However, IFE cannot be used for quantification of MP due to use of antisera for precipitation of the immunoglobulin involved. This on quantification by a scanning using densitometer will give abnormal results not correlating with the actual MP load. UPE and urine IFE have largely been replaced by sFLC assay as the sensitivity of the urine tests for detection of MP is the lowest due to the fact that MPs are not always present in the urine of patients with MG.¹⁵ Immunoglobulin quantification is a good method to identify increased levels of involved MPs. However, as the band is never visualized by nephelometry for immunoglobulin detection and quantification, the technique fails to comment on whether the increase is polyclonal or monoclonal and fails to serve the purpose. The sFLC ratio aims to detect unbalanced serum FLC concentrations and has proved very sensitive in detecting clonal free light chain disease. sFLC may serve as a good diagnostic and prognostic tool and a biomarker for monitoring response to treatment of SPB.

Clinical laboratories often have different workflows for the laboratory evaluation of monoclonal gammopathies. Electrophoresis may or may not be reflexed to IFE at the discretion of the laboratory physician or treating clinician. IFE may detect low-intensity bands missed by electrophoresis, particularly in cases of hypogammaglobulinemia. Further, standard IFE typically assesses for IgG, IgA, IgM, kappa, and lambda and not IgD and IgE. To exclude the presence of MP, it is suggested that IFE, including the use of IgD and IgE antisera, be performed especially in follow-up cases of plasmacytoma along with SPE.¹⁵ In case of no band being

visible on SPE and serum IFE, sFLC analysis may be performed. For diagnosis of plasmacytoma, it is suggested that SPE be performed on suspicion of MG to support diagnosis and also serve as a baseline finding for follow-up in the future. Serum IFE should be mandatory to detect cases capable of being missed on SPE due to a low tumor burden. Communication between the patient, treating clinician, hematopathologist, and clinical chemist is essential to ensure a complete work-up.

Conclusion

- Monoclonal gammopathies have diverse spectra of presentation and are hence aptly classified ranging from monoclonal gammopathy of unknown significance to overt MM apart from other entities such as SP, light chain disease, nonsecretory MM, etc.
- Not all forms of monoclonal gammopathy can be detected by the standard protein electrophoresis alone.
- It is important to clearly delineate which laboratory tests may be used to identify and prognosticate the different forms of monoclonal gammopathy at diagnosis and which tests may be used to prognosticate a disease on follow-up.
- Serum IFE may identify cases of missing M band on SPE in follow-up cases of treated plasmacytoma and hence National Comprehensive Cancer Network guidelines need to be clearly defined indicating the laboratory tests to be included for diagnosis of plasmacytoma and during follow-up.

Funding

None.

Conflict of Interest

None declared.

References

- 1 Kilciksiz S, Karakoyun-Celik O, Agaoglu FY, Haydaroglu A. A review for solitary plasmacytoma of bone and extramedullary plasmacytoma. *ScientificWorldJournal* 2012;2012:895765
- 2 Durie BGM, Salmon SE. A clinical staging system for multiple myeloma. Correlation of measured myeloma cell mass with presenting clinical features, response to treatment, and survival. *Cancer* 1975;36(03):842-854
- 3 Durie BGM, Kyle RA, Belch A, et al; Scientific Advisors of the International Myeloma Foundation. Myeloma management guidelines: a consensus report from the Scientific Advisors of the International Myeloma Foundation. *Hematol J* 2003;4(06):379-398
- 4 Lieboss RH, Ha CS, Cox JD, Weber D, Delasalle K, Alexanian R. Solitary bone plasmacytoma: outcome and prognostic factors following radiotherapy. *Int J Radiat Oncol Biol Phys* 1998;41(05):1063-1067
- 5 Galieni P, Cavo M, Pulsoni A, et al. Clinical outcome of extramedullary plasmacytoma. *Haematologica* 2000;85(01):47-51
- 6 Soutar R, Lucraft H, Jackson G, et al; Guidelines Working Group of the UK Myeloma Forum British Committee for Standards in Haematology British Society for Haematology. Guidelines on the diagnosis and management of solitary plasmacytoma of bone and solitary extramedullary plasmacytoma. *Br J Haematol* 2004;124(06):717-726

- 7 Dimopoulos MA, Mouloupoulos LA, Maniatis A, Alexanian R. Solitary plasmacytoma of bone and asymptomatic multiple myeloma. *Blood* 2000;96(06):2037–2044
- 8 International Myeloma Working Group. Criteria for the classification of monoclonal gammopathies, multiple myeloma and related disorders: a report of the International Myeloma Working Group. *Br J Haematol* 2003;121(05):749–757
- 9 Rajkumar SV, Dimopoulos MA, Palumbo A, et al. International Myeloma Working Group updated criteria for the diagnosis of multiple myeloma. *Lancet Oncol* 2014;15(12):e538–e548
- 10 Caers J, Paiva B, Zamagni E, et al. Diagnosis, treatment, and response assessment in solitary plasmacytoma: updated recommendations from a European Expert Panel. *J Hematol Oncol* 2018; 11(01):10
- 11 Agbuduwe C, Yang H, Gaglani J, Ajithkumar T. Clinical presentation and outcomes of solitary plasmacytoma in a tertiary hospital in the UK. *Clin Med (Lond)* 2020;20(05):e191–e195
- 12 Wilder RB, Ha CS, Cox JD, Weber D, Delasalle K, Alexanian R. Persistence of myeloma protein for more than one year after radiotherapy is an adverse prognostic factor in solitary plasmacytoma of bone. *Cancer* 2002;94(05):1532–1537
- 13 Dingli D, Kyle RA, Rajkumar SV, et al. Immunoglobulin free light chains and solitary plasmacytoma of bone. *Blood* 2006;108(06): 1979–1983
- 14 Chang WI, Koh HK, Yoon SS, Kim HS, Eom KY, Kim IH. The predictive value of serum myeloma protein in solitary plasmacytoma. *Radiat Oncol J* 2020;38(02):129–137
- 15 Jean J, Vergara-Lluri M, Chambliss AB. No monoclonal protein in a patient with CRAB features. *Clin Chem* 2021;67(12):1584–1588